

Case Analysis

Managing Cytomegalovirus Colitis: Experience from 22 Patients at the Kaohsiung Veterans General Hospital

Yuen-Fui Li¹

Jui-Ho Wang²

¹Division of General Surgery, Department of Surgery, Armed Forces Taoyuan General Hospital, Taoyuan,

²Division of Colon & Rectal Surgery, Department of Surgery, Kaohsiung Veterans General Hospital, Kaohsiung, Taiwan.

Key Words

Cytomegalovirus colitis;
Immunohistochemistry

Purpose. Cytomegalovirus (CMV) colitis usually occurs in patients with inflammatory bowel disease (IBD) or those who are immunocompromised. However, clinical manifestations, endoscopic appearance and the clinical course vary. This report presents our experience with diagnosis and treatment of CMV colitis at the Kaohsiung Veterans General Hospital.

Methods. Twenty-two patients, from 2001 to 2011, with CMV colitis were retrospectively analyzed. Their underlying comorbidities, endoscopic findings, treatment and outcomes were assessed.

Results. Most patients were older than 60 years old. Common comorbidities included cardiovascular disease, pulmonary disease and sepsis. Most patients presented with diarrhea; others presented with fever, abdominal pain and hematochezia. All patients were diagnosed with immunohistochemistry (IHC). Colitis with or without ulcer was the most common endoscopic appearance. Eighteen patients received antiviral therapy and 12 of them had symptomatic relief. Three patients who underwent surgery eventually expired.

Conclusion. CMV colitis can present with variable clinical manifestations. Full-length colonoscopy and tissue biopsy confirmation with immunohistochemical stain is required to diagnose CMV colitis in most cases. Antiviral therapy is still the mainstay of treatment. The prognosis of such patients is closely related to their underlying comorbidities. Early recognition and a high degree of suspicion of this clinical entity is needed to ensure a better prognosis of the patients.

[J Soc Colon Rectal Surgeon (Taiwan) 2012;23:175-182]

Cytomegalovirus (CMV) is a member of the Herpesvirus family, and the prevalence of CMV antibodies ranges from 40% to 100% in various societies.¹ After primary infection, the infected individuals become virally latent.² Reactivation usually occurs in immunocompromised patients and causes severe diseases. Reactivation in immunocompetent

patients has also been reported, but with more benign and self-limited course.^{3,4}

The colon is one of the most commonly involved organs in CMV disease in addition to other organs such as the lungs, retina, central nervous system and liver.^{1,2} Patients of CMV colitis usually present with fever, abdominal pain, diarrhea, hematochezia and

Received: March 19, 2012.

Accepted: July 2, 2012.

Correspondence to: Dr. Jui-Ho Wang, Division of Colon & Rectal Surgery, Department of Surgery, Kaohsiung Veterans General Hospital, No. 386, Ta-Chung 1st Rd., Kaohsiung, Taiwan. Tel: +886-7-342-2121; Fax: +886-7-342-2288; E-mail: wang@vghks.gov.tw

rarely intestinal perforation.¹ The large variety of clinical manifestations, depending on the site of infection, can make the diagnosis difficult.

Currently, the diagnosis of CMV colitis depends on histological immunohistochemistry (IHC).⁵ This prompted us to review and analyze all the patients with pathologically proven CMV colitis at our institution in order to improve on the methods used to treat such individuals in the future.

Patients and Methods

From January 2001 to November 2011, 22 patients were pathologically diagnosed as having CMV colitis at the Kaohsiung Veterans General Hospital, Taiwan. We confirmed the diagnosis of CMV colitis by IHC with a mixture of two monoclonal antibodies that recognized CMV immediate early and early antigens. Tissue specimens were obtained by endoscopy or operation. We followed these patients from six months to two years (median one year). Information was retrospectively gathered using the patients' medical charts and computerized files. Data collected included age, gender, underlying comorbidities, symptoms, diagnostic tools, endoscopic finding, treatment and clinical outcomes.

Results

Characteristics of patients

The demographic characteristics of the 22 patients and their underlying comorbidities are analyzed. Most of the patients were elderly and predominantly male. The mean age of the patients was 56.7 years and this ranged from 14 to 84 years. Seven patients had AIDS. Most of the patients had multiple comorbidities including cardiovascular and pulmonary disease. Other common comorbidities include sepsis, urinary tract infection, diabetes mellitus, renal insufficiency and malignancy. None of the patients with malignancy were receiving chemotherapy at the time of colitis. Three patients had undergone organ transplantation. Two patients had ulcerative colitis (UC). One patient

had been taking long-term steroids for treatment of chronic obstructive pulmonary disease. There were a total number of six patients receiving immunosuppressive therapy (Tables 1 and 2).

Clinical manifestations

Most patients presented with acute diarrhea (82%). Other patients presented with fever, abdominal pain, hematochezia and body weight loss (Table 3).

Diagnostic investigations

All patients underwent endoscopy. Endoscopic biopsies were performed and the specimens were sent for pathological studies. Two patients received repeated endoscopy, due to undetermined etiology of persistent gastrointestinal symptoms. CMV inclusion bodies were found in 18 of the 22 patients (82%) and

Table 1. Demographic data of the study population

Number of patients (n)	22
Mean age (years)	56.7 (14-84)
> 60 years old (%)	12 (54.5%)
Male	15
Female	7

Table 2. Underlying co-morbidities of the study population

Underlying co-morbidities	n (%)
Cardiovascular disease ^a	11 (50%)
Pulmonary disease	9 (41%)
Non-tuberculous infection	4 (18%)
Tuberculous infection	4 (18%)
Non-infectious	1 (5%)
Sepsis	8 (36%)
AIDS	7 (32%)
Urinary tract infection	4 (18%)
Diabetes mellitus	5 (23%)
Renal insufficiency ^b	3 (14%)
Malignancy	4 (18%)
With chemotherapy	0 (0%)
Without chemotherapy	4 (18%)
Transplant	3 (14%)
Ulcerative colitis	2 (9%)
Bedridden	3 (14%)
Under immunosuppressive therapy	6 (27%)

^a including coronary artery disease and hypertension; ^b including acute and chronic renal insufficiency.

all the pathological diagnosis of CMV colitis was confirmed with IHC (100%). Two of the four patients received blood culture for CMV had positive culture. Only a few patients underwent CMV serology and direct detection of CMV pp65 antigen in this study, with a sensitivity of 75% and 100%, respectively (Table 4).

Colonoscopy findings

Only three of the patients underwent a full-length colonoscopy, and a flexible sigmoidoscopy was performed for the remaining patients. For one patient it actually took five times of flexible sigmoidoscopy to achieve the final diagnosis of CMV colitis. The main endoscopic findings in our population are categorized into 4 groups: normal, ulcer alone, colitis alone, or ulcer with colitis. One (5%) patient had macroscopically normal mucosa. Another (5%) had discrete ulcer alone. Ten (45%) patients had only colitis. The remaining 10 (45%) patients had ulcer combined with colitis (Table 5).

Treatment and clinical outcomes

Eighteen patients received ganciclovir therapy for

Table 3. Clinical manifestation of 22 patients with CMV colitis

Clinical manifestation	n	%
Diarrhea ^a	18	82%
Acute	11	50%
Chronic and persistent	7	32%
Fever	9	41%
Abdominal pain	9	41%
Hematochezia	8	36%
Body weight loss	4	18%

^a Acute diarrhea defined as diarrhea < 2 weeks, whereas persistent diarrhea 2-4 weeks and chronic diarrhea as > 4 weeks.

Table 4. Diagnostic examination made in 22 patients

Diagnostic tools	Number of patients receiving examination	Number of patients with positive findings	Sensitivity (%)
Histology (H & E)	22	18	82%
Histology (Immunohistochemistry)	22	22	100%
CMV culture (blood)	4	2	50%
CMV serology (IgM)	4	3	75%
pp65 antigen	1	1	100%

two to three weeks. Twelve patients improved after receiving antiviral therapy. Three patients died due to polymicrobial sepsis and multiple organ failure. One patient was a HIV carrier and died of cryptococcus meningitis. Two patients had poor response and underwent further surgical intervention. Two of three patients who did not receive antiviral therapy died. There were a total number of three patients who underwent colectomy. The first patient was operated due to persistent hematochezia. The second one was operated owing to colon perforation and massive bloody stools. The third patient had uncontrolled lower gastrointestinal bleeding and hypovolemic shock. All three patients finally expired due to sepsis after receiving surgery. The successfully treated patients were followed from six months to two years, with one case of relapse within one month. The patient finally expired due to sepsis. Others remained complete remission (Fig. 1 and Table 6).

Discussion

CMV infection is a common, opportunistic infection and its actual prevalence rate in Taiwan remains unknown. It can be acquired via exposure to CMV during delivery, breast feeding, sexual contact, transfusion, or organ transplantation.¹ Most infected individuals are asymptomatic and become latent lifelong. Reactivation in immunocompromised patients usually

Table 5. Endoscopic appearance of CMV colitis

Appearance	n	%
Normal	1	5%
Ulcer alone	1	5%
Colitis alone	10	45%
Ulcer with colitis	10	45%

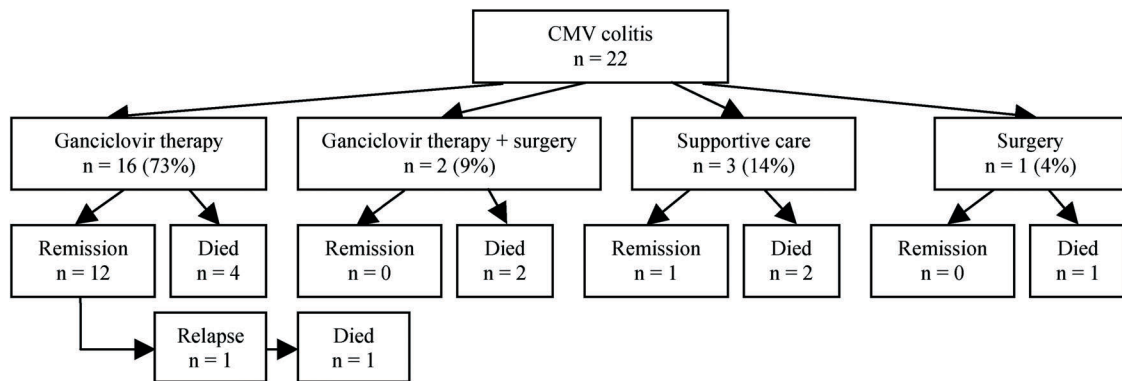


Fig. 1. Clinical course and outcomes of the 22 patients with CMV colitis.

Table 6. Characteristics of patients who died

Sex/age	Underlying disease	Presenting symptoms	Antiviral therapy	Surgery	Cause of death
M/45 (relapse)	Wegener's granulomatosis (immunosuppressive therapy)	Abdominal pain, diarrhea, fever	Y	N	Sepsis
M/57	Ulcerative colitis (immunosuppressive therapy)	Hematochezia, abdominal pain, colon perforation	Y	Y	Sepsis
F/74	Chronic renal insufficiency, sepsis	Persistent hematochezia, abdominal pain	Y	Y	Sepsis
F/49	Chronic myeloid leukemia (immunosuppressive therapy)	Fever, diarrhea	N	N	Sepsis
M/66	Pneumonia, sepsis	Hematochezia	N	N	Sepsis
M/14	Acute myeloid leukemia, Graft-versus-host disease (immunosuppressive therapy)	Abdominal pain, hematochezia	Y	N	Sepsis
M/20	AIDS	Abdominal pain, diarrhea	Y	N	Cryptococcus meningitis
F/71	Sepsis	Abdominal pain, diarrhea	Y	N	Sepsis
M/70	Urinary tract infection	Abdominal pain, diarrhea	Y	N	Sepsis
F/77	Acute renal failure	Hematochezia, hypovolemic shock	N	Y	Sepsis

causes severe disease. Organs usually involved in CMV infection include the lung, retina, liver and gastrointestinal tract. The colon is the most frequent site of severe CMV infection, followed by the central nervous system.¹⁻³

The pathogenesis of colitis is still uncertain. Some have proposed that epithelial cells and macrophages are latently infected, and that CMV reactivation in endothelial cells may initiate the colitis. Others hypothesize that the presence of other colon disorders may attract latently infected macrophages, resulting in up-regulation of viral replication.⁴ CMV reactivation is thought to be triggered by tumor necrosis factor (TNF), catecholamines, and proinflammatory prostaglandins, etc.⁵

CMV colitis can also occur in immunocompetent individuals. Most cases are self-limiting but may also cause severe colitis with significant morbidity and mortality.⁴ In a meta-analysis of CMV colitis in 44 immunocompetent host, eight patients had chronic renal insufficiency, six patients had diabetes, three patients had untreated malignancy, two were pregnant and the ten patients were without coexisting medical problems.¹ The etiology of CMV colitis in immunocompetent individuals is still unclear. Some suggested that colonic mucosal injury can predispose patients to CMV colitis. Predisposing factors include *Shigella* dysentery, anal intercourse, cardiogenic shock, allergic colitis, aspirin, NSAIDs, chemotherapy and radiation therapy.¹

In our study, the patients with CMV colitis were mainly elderly individuals with multiple comorbidities. These patients were not considered as immunocompetent individuals due to their weakened immunity. Comorbidities like diabetes mellitus, chronic renal failure and malignancies have been reported to cause immune-modulation. Aging also contributes to cause a decline in cellular and humoral immunity.² Therefore, the prognosis of these patients was poor and they had a higher mortality rate.

The most frequent symptom of CMV colitis was non-bloody diarrhea, followed by hematochezia. Other common symptoms of CMV colitis included fever, abdominal pain, nausea, vomiting and weight loss.³ The high variety of these non-specific symptoms make the diagnosis of CMV colitis rather difficult. Therefore, a high degree of alertness is needed on the part of medical practitioners to suspect CMV colitis in symptomatic patients, particularly if they are immunocompromised.

A number of techniques can be used to diagnose CMV infection; including endoscopic biopsy, histology, serology, viral culture, CMV antigen testing and CMV DNA testing.⁵ Most patients in our study underwent flexible sigmoidoscopy. Only three patients underwent full-length colonoscopy. The results are contrary to previous reports in which up to 30% of CMV colitis was located at the ascending colon.^{5,6} The discrepancy may be due to our small population size. Most authors of other literatures insisted that full-length colonoscopy is necessary to make an early and accurate diagnosis of CMV colitis.¹

Various endoscopic findings can be observed in patients of CMV colitis. The common findings are ulcers, erosions and mucosal hemorrhage.² Previous studies have reported CMV colitis involving macroscopically normal mucosa. Latent CMV infection without active viral replication can occur in up to 2% of normal colonic disease.² The authors concluded that random biopsies should be performed throughout the colon regardless of colonoscopic findings, even from normal mucosa.¹ In our opinion, it is practically unnecessary.

Nowadays, histological confirmation with IHC is considered as gold standard for diagnosis of CMV colitis. The sensitivity of IHC to detect CMV infection

can approximate 93%.⁵ In our study, we also made the diagnosis of CMV colitis based on immunohistochemical staining. Compared with conventional H & E stain, it is more sensitive (93% vs. 87%) and has excellent specificity (both approximate 100%).^{5,7} CMV IgM serologic test was performed in four patients. However, CMV IgM antibody levels usually drop within 2-3 months, and are undetectable at 12 months;⁵ thus, it is unreliable in detecting chronic CMV infection. CMV antigen test (pp65) was also performed in one patient. The CMV antigen test detects late structural protein pp65 produced in leukocytes via staining with immunofluorescent pp65-specific monoclonal antibodies, with a sensitivity of 60-100% and a specificity of 83-100%.⁵ It is a rapid diagnostic technique that allows for the early treatment of CMV colitis.⁸ However, it is impossible to compare the sensitivity of these diagnostic tools in our study since only one patient underwent the antigen test. Further prospective investigation is needed to estimate the accuracy of various diagnostic tools in cases of suspected CMV colitis.

A particular group of patients in our study had acquired immunodeficiency syndrome (AIDS). According to the related literature, CMV may be present in the gastrointestinal tracts of 30-40% of AIDS patients. However, only about 74% of these patients developed clinically apparent CMV disease.⁶

Two of our patients had underlying ulcerative colitis. It is well known that CMV infection exacerbates pre-existing inflammatory bowel disease (IBD) and results in a higher rate of complications and mortality.⁹ However, it is still uncertain whether CMV infection has an active role in IBD or whether it exists coincidentally. Some authors suggested that CMV is often present as an innocent bystander and CMV primary infection may masquerade as a flare-up of pre-existing IBD.¹⁰ Elderly patients with severe steroid-resistant ulcerative colitis may be at particular risk for CMV infection. Dense CMV infection predominantly in endothelial cells may be a useful marker for clinically relevant CMV infection.¹¹ Proper diagnosis of CMV colitis in such patient may prevent unnecessary colectomy, which leads to mortality.⁸ Some case series of CMV infection in IBD patients have reported a colectomy rate of 64% and mortality rate of 44%.⁷

The anastomotic complications are also poorly tolerated.¹² Therefore, recognition and proper diagnosis of this particular group of patients is crucial.

Ganciclovir is the treatment of choice for treating gastrointestinal CMV disease, with a recommended dosage of 5 mg/kg administered intravenously every 12 hours for 2-3 weeks.^{5,6} An alternative is valacyclovir, but this may result in a higher mortality rate.⁶ Myelotoxicity is the most common side effect, and up to 40% of treated patients will experience bone marrow suppression. Foscarnet is given in cases of ganciclovir resistance or intolerance.⁵

The indications of surgery in CMV colitis include massive hemorrhage, bowel perforation with generalized peritonitis and toxic megacolon. Refractory to medical treatment also warranted surgical intervention.¹²

In our study, ten of the 22 patients died, including one case of relapse within one month. Most of them were elderly and had multiple comorbidities. Four of them were receiving immunosuppressive therapy. One patient was a HIV carrier in AIDS status and was considered immunocompromised. Three patients who underwent colectomy finally expired due to sepsis. It had been reported that elderly patients, male gender, surgery, and immune-modulating diseases were associated with a worsened survival.⁵ Unless indicated, surgical intervention is not suggested due to high mortality and morbidity.¹² In order to improve the prognosis of such patients, early recognition and a high degree of suspicion of this clinical entity is required.

There are some limitations in our study that are worth noting: first, only hospitalized patients were evaluated. Thus, we could not assess the true incidence and scope of clinical manifestations of CMV colitis. Second, few diagnostic tools were used and the number of patients was limited. Therefore, we cannot compare the sensitivity of different diagnostic methods. Finally, no follow-up colonoscopy was performed in our patients after completing antiviral therapy. Thus, the results of antiviral therapy cannot be clearly assessed.

Conclusion

In conclusion, this study demonstrates that CMV

colitis presents with variable clinical manifestations. Some patients may develop a life-threatening colitis. Full-length colonoscopy and tissue biopsy confirmation with immunohistochemistry is required to diagnose CMV colitis in most cases. Antiviral therapy is still the mainstay of treatment, whereas surgery is not. The prognosis of the patient is closely related to their underlying comorbidities. Early recognition and a high degree of suspicion of this clinical entity is needed to ensure a better prognosis for such patients.

References

1. Kim CH, Banhg S, Kang KJ, Ku BH, Jo YC, Kim JY, Chang DK, Son HJ, Rhee PL, Kim JJ, Rhee JC, Kim YH. Cytomegalovirus colitis in patients without inflammatory bowel disease: a single center study. *Scand J Gastroenterol* 2010; 45:1295-301.
2. Einbinder Y, Wolf DG, Pappo O, Migdals A, Tsvangs E, Ackerman Z. The clinical spectrum of cytomegalovirus colitis in adults. *Aliment Pharmacol Ther* 2008;27:578-87.
3. Rafailidis PI, Mourtzoukou EG, Varbobitis IC, Eleni GM, Ioannis CV, Falagas ME. Severe cytomegalovirus infection in apparently immunocompetent patients: a systematic review. *Virology* 2008;5:47-53.
4. Enid K, Laurence EB, Riad K. Cytomegalovirus colitis in the immunocompetent host: an overview. *Scand J Infect Dis* 1998;30:559-64.
5. Ahmed K, Bret L. Cytomegalovirus colitis complicating inflammatory bowel disease. *Am J Gastroenterol* 2006;101: 2857-65.
6. Chuah SK, Changchien CS, Kuo CM, Wu KL, Chiu KW, Chiu YC, Liu JW, Eng HL, Chiou SS. Gastrointestinal tract cytomegalovirus disease in southwestern Taiwan: a clinical study of 1950 endoscopic biopsies. *Chang Gung Med J* 2005;28:467-75.
7. Kim JJ, Simpson N, Klipfel N, DeBose R, Barr N, Laine L. Cytomegalovirus infection in patients with active inflammatory bowel disease. *Dig Dis Sci* 2010;55:1059-65.
8. Neelima R, Wilcox CM. Diagnosis and management of cytomegalovirus infections in the GI tract. *Gastroenterol Hepatol* 2007;1:287-94.
9. Dorna R, Abderrhman O, Jorge M, Scott K, Domenico C. CMV colitis mimicking recurrent inflammatory bowel disease: report of three cases. *Am Surg* 2007;73:58-61.
10. Saussure P De, Lavergne-slove A, Mazon MC, et al. A prospective assessment of cytomegalovirus infection in active inflammatory bowel disease. *Aliment Pharmacol Ther* 2004; 20:1323-7.
11. Akifumi K, Haruhiko O, Takeyasu S, Yoichi A, Katsuyoshi

H. Clinicopathologic characteristics of clinically relevant cytomegalovirus infection in inflammatory bowel disease. *J Gastroenterol* 2007; 42:823-9.

12. Albu E, Mukherjee A, Rao D, Sehonanda A, Pai BN, Gerst

PH. Emergency surgery for generalized peritonitis caused by cytomegalovirus colitis in a patient with AIDS. *Am Surg* 1999;65:397-8.

病例分析

巨細胞病毒結腸炎：高雄榮總 22 例的經驗回顧

李元魁¹ 王瑞和²

¹國軍桃園總醫院 一般外科

²高雄榮民總醫院 大腸直腸外科

目的 巨細胞病毒結腸炎常發生在發炎性腸疾或免疫力不全的病患上，但其臨床表徵、內視鏡病變和預後有很大差異性，這篇文章針對本院對巨細胞病毒結腸炎的治療經驗提供分享。

方法 本研究收集自 2001 至 2011 年間，在本院有紀錄之巨細胞病毒結腸炎的 22 例病患，分析其臨床表徵、合併疾病，內視鏡病變、治療及預後。

結果 大部分病患大於 60 歲，最常見的合併疾病包括心血管疾病、肺疾和敗血症，最常見的臨床症狀為腹瀉、發燒、腹痛和便血，所有病患皆用免疫組織化學法診斷，最常見的內視鏡病變為合併潰瘍的結腸炎或單獨性結腸炎，有 18 名病患接受抗病毒藥物治療，其中 12 名病患治療後症狀緩解，三名接受手術治療的病患最終死亡。

結論 巨細胞病毒結腸炎的症狀變化很大，完整的大腸鏡檢查和組織切片合併免疫組織化學染色可診斷大部分的病例，抗病毒療法是主要的治療方式，病患的預後與他們合併的疾病相關，高度警覺和早期診斷可使此類病患有較好的預後。

關鍵詞 巨細胞病毒結腸炎、免疫組織化學法。