

Case Report

Gastrointestinal Perforation in Patients with Metastatic Colorectal Cancer treated with Bevacizumab (Avastin) – Three Cases Report

Shih-Chang Chang¹
Ming-Hung Shen¹
Henry Hsin-Chung Lee¹
Yung-Chuan Sung²

¹*Section of Colorectal Surgery, Department of Surgery*

²*Division of Hematology-Oncology, Department of Internal Medicine, Cathay General Hospital, Taipei, Taiwan*

Bevacizumab (Avastin), a humanized monoclonal antibody against vascular endothelial growth factor (VEGF), demonstrates improved survival when combined with chemotherapy in the treatment of metastatic colorectal cancer (mCRC) patients. Bowel perforation is a serious complication of unknown etiology associated with the use of bevacizumab. Here we report three cases of metastatic colorectal cancer patients, who, after receiving chemotherapy regimen in combination with bevacizumab treatment, were found suffering from intestinal perforation.

[*J Soc Colon Rectal Surgeon (Taiwan) 2011;22:39-44*]

Key Words

Bevacizumab;
Intestinal perforation;
Metastatic colorectal cancer

Targeting VEGF Bevacizumab (Avastin) has been approved by the U.S. Food and Drug Administration in February 2004 and the European Medicines Agency in January 2005 for use in metastatic colorectal cancer (mCRC). In a phase III clinical trial it was shown to improve survival and progression-free survival and an increased response rate as compared to a chemotherapy (IFL) regimen containing bolus fluorouracil (5-FU), leucovorin (LV), and irinotecan (CPT-11).¹ Bevacizumab inhibits tumor angiogenesis, an important process in tumor growth and the formation of metastases. Inhibition of VEGF not only suppresses the growth of new blood supplying vessels of the tumor, but leads to “normalization” of existing tumor vessels, thereby reducing interstitial fluid pressure and enhancing the efficacy of chemotherapeutic

drugs.² Avastin is the first anti-angiogenesis drug used in colorectal cancer, which in contrast to conventional treatment with 5-FU, CPT-11, and oxaliplatin, does not have serious myelotoxicity or neurotoxicity.³ The reported side effects of Avastin include hypertension, proteinuria, thromboembolic events, delayed wound healing, gastrointestinal bleeding and bowel perforation.^{1,4,5} Gastrointestinal perforation associated with bevacizumab has been defined as the finding of intraperitoneal air with or without gastrointestinal or enterocutaneous fistula. Morbidity and mortality from GI perforation of using Avastin are high, and therefore clinically it is important to recognize it early.

Though being with a reported rate lower than 2%, Avastin-associated bowel perforation has been found potentially fatal.^{1,5} Reported herein are three cases of

Received: October 25, 2010.

Accepted: March 16, 2011.

Correspondence to: Dr. Yung-Chuan Sung, Division of Hematology-Oncology, Department of Internal Medicine, Cathay General Hospital, No. 280, Section 4, Jen-Ai Road, Taipei, Taiwan. Tel: +886-2-2708-2121; Fax: +886-2-2709-2063

bowel perforations that occurred after using bevacizumab combined with chemotherapy in mCRC patients.

Cases Report

Case 1

A stage IV 69-year-old woman with ascending colon cancer and multiple liver metastases underwent 5 cycles of chemotherapy with FOLFIRI and Bevacizumab. Her comorbidities including diabetes mellitus, hypertension, and coronary heart disease were medically treated. Based on clinical staging results of stage IV without colonic obstruction as, FOLFIRI and Bevacizumab regimen were administered as neoadjuvant chemotherapy, and the last cycle was on December 19th, 2008. Having suffering from RUQ pain and abdominal fullness for three days after the last chemotherapy, the patient underwent abdominal CT scan, which showed: 1) colon cancer involving proximal descending colon, cecum, and terminal ileum, suspicious of tumor perforation with some free air; 2) inflammation with air-pockets at right iliac region (Fig. 1). Due to tumor perforation, ileocecal resection with end ileostomy was performed on December 24th, 2008; however, progression of septic shock from necrotizing myofasciitis was observed and found refractory to resuscitation. The patient expired on December 31th, 2008.

Case 2

A 52-year-old man with rectal cancer, pT3N2M0

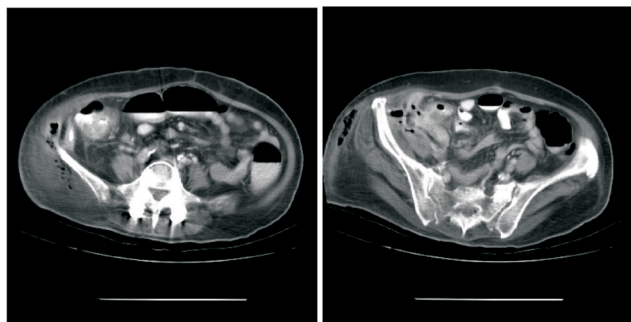


Fig. 1. Tumor perforation with free air at adjacent RLQ abdomen.

stage IIIc, post LAR at other hospital on January 16th, 2008. With anastomotic leakage, a T-colostomy was performed on January 21th, 2008. He was transferred to our hospital for adjuvant CCRT with 5 cycles of FOLFOX-4. T-colostomy was takedown on September 29th, 2008. Due to recurrence and bone metastasis, 5 cycles of FOLFIRI with bevacizumab were given. RUQ erythematous change and profuse amount of stool discharge from stoma closure wound on June 26th, 2009 were noted. Abdominal and pelvic CT on June 29th, 2009 showed 1) focal anterior right lower abdominal wall defect; 2) suspected local recurrent rectal tumor; 3) bony metastasis involving pelvis and spine, with right pelvic mass around iliac bone (Fig. 2). The enterocutaneous fistula was diagnosed. Fistulography confirmed the communication with transverse colon (Fig. 3). In view of bone and brain metastasis, the conservative treatment with antibiotics was performed. The fistula was spontaneously closed. The patient, however, expired on September 7th, 2009 due to multiple metastases including brain metastasis.

Case 3

A 52-year-old woman of an obstructive rectal cancer with ovary invasion, pT4N2M0 stage IIIc received Hartmann's procedure, total hysterectomy and bilateral salpingoophorectomy on October 22th, 2008. Adjuvant CCRT with Tegafox and radiotherapy were given. The follow-up tumor markers showed elevation in June 2009 indicative of recurrence, and abdominal CT showed multiple hepatic metastases. After 5 cycles of FOLFIRI + Bevacizumab, she had feculent passage from anus. Her colostoma was patent but the amount of stool was decreasing. Abdominal

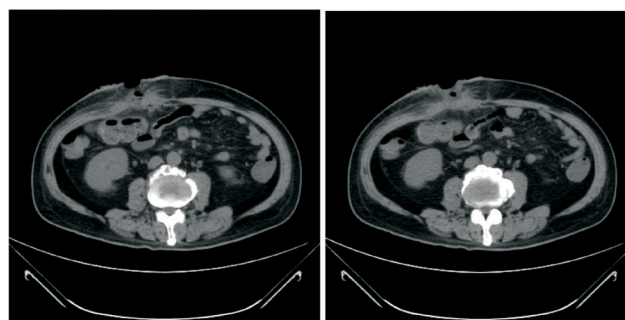


Fig. 2. Focal anterior right lower abdominal wall defect.

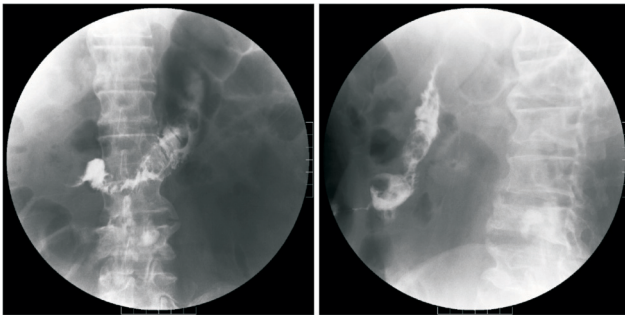


Fig. 3. Fistulography showed fistula communicating with transverse colon.

and pelvic MRI showed enterorectal fistula with communication to small bowel and stump of upper rectum (Fig. 4). She received supportive treatment and diet adaption only, and lived for more than one year.

Discussion

Bevacizumab (Avastin) is a humanized monoclonal antibody that targets vascular endothelial growth factor, and has been demonstrated to counteract metastatic colorectal cancer (mCRC) in combination use with chemotherapy. In phase II trial for the treatment of colorectal cancer, the addition of bevacizumab to 5-FU plus LV increased the response rate, the median time to progression and the median duration of survival.^{4,5}

In a large (N = 813) randomized, double-blind, placebo-controlled phase III trial of mCRC, bevacizumab in combination with IFL showed a 30% significant increase in overall survival compared with IFL alone (20.3 vs 15.6 months, $p \leq 0.001$) and progression-free survival by 71% (from 6.2 to 10.6 months, $p \leq 0.001$).¹ A meta-analysis including five clinical randomized trials of 3103 intent-to-treat mCRC patients, with 1559 patients in the chemotherapy-plus-bevacizumab arm, showed that the addition of bevacizumab to chemotherapy resulted in both a clinically statistically significant reduction in the risk of dying or progression/death compared with the chemotherapy-alone group.⁶

In the initial trial of bevacizumab in combination with FU/LV or IFL, the most common side effects were hypertension, proteinuria, leukopenia and diar-

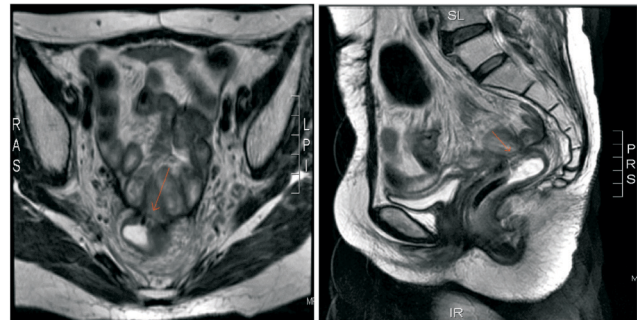


Fig. 4. Abdominal and pelvic MRI showed fistula of small bowel to stump of upper rectum.

rhea. Less common, but serious complications such as bleeding, thromboembolic events and bowel perforation occurred with a frequency of less than 2%.^{1,5,6} Among the side effects, bowel perforation associated with bevacizumab remains a rare, but lethal complication.

The overall incidence of grade 5 GI perforation (death) was 0.3% (95% CI 0.1-0.5%) according a meta-analysis of 11 phase III trials. Among patients with bevacizumab-associated perforation, the meta-analysis showed that the mortality of GI perforation associated with bevacizumab was 21.7% (11.5-37.0), whereas the mortality of GI perforation associated with controls was 15.7% (4.6-41.9).⁷

The same meta-analysis study also showed that the risk of perforation associated with bevacizumab varied with tumor types. The risk was significantly increased in patients with colorectal cancer who received bevacizumab (relative risk 3.10, 95% CI 1.26-7.63; $p = 0.013$).⁷

From 2007/March to 2009/December there were 60 patients treated with bevacizumab in our hospital and the three cases with GI perforation were all mCRC patients. A case series report with 1442 patients treated with bevacizumab showed a 1.7% (24/1442) incidence of GI perforation.⁸ The breakdown of these 24 patients by disease site was as follows: ovarian (3/50, 6%), gastroesophageal (2/38, 5.3%), pancreatic (7/141, 5%), unknown primary (1/60, 1.7%), lung (1/67, 1.5%), colorectal (6/478, 1.3%), and renal cell (4/269, 1.5%). The majority of patients ($n = 19$, 79%) were initially managed non-operatively. Only five (21%) patients ultimately underwent surgical exploration with a subsequent an-

astomotic leak developed in one patient. The overall 30-day mortality rate was 12.5% (3/24), and the 60-day mortality rate was 25% (6/24).

Patients with ovarian cancer and renal cell cancer also exhibit a higher risk of gastrointestinal perforation.^{8,9} Bevacizumab-associated GI perforation in patients with recurrent ovarian carcinoma occurred in 4% (6/160) of a retrospective study. The prognosis was poor and treatment should be individualized.¹⁰

The suggested predisposing risk factors for GI perforation are the use of steroids, underlying cancer, peptic ulcer disease, diverticulitis, chemotherapy-induced colitis, a history of abdominal radiation, abdominal carcinomatosis and bowel obstruction.^{7,11-14} The observed higher incidence of gastrointestinal perforation seemed to be in patients with intact primary tumors, a recent history of sigmoidoscopy or colonoscopy, or previous adjuvant radiotherapy.¹⁴ In our first case, the patient had an intact primary tumor over the ascending colon. In our second case, the patient had rectal cancer recurrence and previous colostomy anastomosis wound. In the third case, the patient had pelvic adjuvant radiotherapy.

Several possible mechanisms could be involved in the pathogenesis of bevacizumab-associated GI perforation.¹⁵ One possibility is that the perforations are tumor-related. In case one, subsequent chemotherapy with bevacizumab might promote tumor regression and necrosis of the tumor by stabilization of the tumor vasculature and a decrease in the permeability and interstitial pressure so as to predispose the patient to developing a bowel perforation.¹⁶ Another possibility is that bevacizumab could limit the blood flow to the splanchnic vasculature via thrombosis or vasoconstriction. A marginal blood supply to an area of the bowel could potentially lead to bowel infarction and then perforation. Scappaticci et al. suggested that the use of bevacizumab within 28 days of operation could increase the risk of wound healing complications after primary cancer surgery in colorectal cancer patients.¹¹ For the first case, we assumed that tumor necrosis resulted in the cecal perforation. The perforation site was located on the primary tumor of the colon. For the second case, although the pathogenesis of the patient's intestinal perforation was not entirely understood, we presumed that colostomy anastomosis was

the predisposing factor for intestine perforation and enterocutaneous fistula. Bevacizumab might damage the structure and function of gastrointestinal vasculature and result in ischemic perforation of the normal bowel or anastomotic site.¹⁷ For the third case, ischemic bowel complications were more frequent in patients with a history of pelvic irradiation.¹³

The reported locations of perforation include the stomach, small bowel and large bowel.^{1,5,13,18} The large bowel is the most common site of bowel perforation after chemotherapy combined with bevacizumab. In our cases, we observed that the bowel perforation developed after the 5th cycle of chemo-target therapy, which seemed to be the same as the 71 day median time to perforation after the initiation of bevacizumab treatment showed in case series report.⁸

A meta-analysis study showed that the increased risk of bevacizumab-associated perforation seemed to be dose-dependent as the relative risk was found to be greater (2.67:1.61) at a dose of 5 mg/kg per week than at 2.5 mg/kg per week.⁷ Our routine bevacizumab dose is 5 mg/kg per 2 weeks.

Although bowel perforation remains an uncommon event in the treatment with bevacizumab, it is life-threatening whether induced by bevacizumab alone or as a result of combination chemotherapy.^{1,5} Careful observation and identifying potential risk factors are imperative for those patients who are administered bevacizumab in combination with chemotherapy. MCRC patients treated with bevacizumab should be closely monitored for the signs and symptoms of bowel perforation. The resuscitation and early intervention should be performed and the non-operative treatment may be considered first. In regard to the best treatments in the setting of advanced cancer, the treatment strategy should be the conclusions of multidisciplinary discussions that involve the surgeon, oncologist, radiologist, ancillary staff, family members, and the patient.

References

1. Hurwitz H, Fehrenbacher L, Novotny W, Cartwright T, Hainsworth J, Heim W, Berlin J, Baron A, Griffing S, Holmgren E, Ferrara N, Fyfe G, Rogers B, Ross R, Kabbinavar F. Bevacizumab plus irinotecan, fluorouracil, and leucovorin

- for metastatic colorectal cancer. *N Engl J Med* 2004;350:2335-42.
- Jain RK, Tong RT, Munn LL. Effect of vascular normalization by antiangiogenic therapy on interstitial hypertension, peritumor edema, and lymphatic metastasis: insights from a mathematical model. *Cancer Res* 2007;67:2729-35.
 - Simpson D, Dunn C, Curran M, Goa KL. Oxaliplatin: a review of its use in combination therapy for advanced metastatic colorectal cancer. *Drugs* 2003;63:2127-56.
 - Kabbinavar F, Hurwitz H, Fehrenbacher L, Meropol NJ, Novotny WF, Lieberman G, Griffing S, Bergsland E. Phase II, randomized trial comparing bevacizumab plus fluorouracil (FU)/leucovorin (LV) with FU/LV alone in patients with metastatic colorectal cancer. *J Clin Oncol* 2003;21:60-5.
 - Chen HX, Mooney M, Boron M, Vena D, Mosby K, Grochow L, et al. Phase II multicenter trial of bevacizumab plus fluorouracil and leucovorin in patients with advanced refractory colorectal cancer: an NCI Treatment Referral Center Trial TRC-0301. *J Clin Oncol* 2006;24:3354-60.
 - Cao Y, Tan A, Gao F, Liu L, Liao C, Mo Z. A meta-analysis of randomized controlled trials comparing chemotherapy plus bevacizumab with chemotherapy alone in metastatic colorectal cancer. *Int J Colorectal Dis* 2009;24:677-85.
 - Hapani S, Chu D, Wu S. Risk of gastrointestinal perforation in patients with cancer treated with bevacizumab: a meta-analysis. *Lancet Oncol* 2009;10:559-68.
 - Badgwell BD, Camp ER, Feig B, Wolff RA, Eng C, Ellis LM, Cormier JN. Management of bevacizumab-associated bowel perforation: a case series and review of the literature. *Ann Oncol* 2008;19:577-82.
 - Cannistra SA, Matulonis UA, Penson RT, Hambleton J, Dupont J, Mackey H, Douglas J, Burger RA, Armstrong D, Wenham R, McGuire W. Phase II study of bevacizumab in patients with platinum-resistant ovarian cancer or peritoneal serous cancer. *Journal of Clinical Oncology* 2007;25:5180-6.
 - John PD, William PT, Oliver Z, Jason K, Paul JS, Lisa AS, Nadeem R, Abu-R, Dennis SC, Carol A, Richard RB. Incidence and management of bevacizumab-associated gastrointestinal perforations in patients with recurrent ovarian carcinoma. *Gynecologic Oncology* 2010;116:335-9.
 - Scappaticci FA, Fehrenbacher L, Cartwright T, Hainsworth JD, Heim W, Berlin J, Kabbinavar F, Novotny W, Sarkar S, Hurwitz H. Surgical wound healing complications in metastatic colorectal cancer patients treated with bevacizumab. *J Surg Oncol* 2005;91:173-80.
 - Gordon MS, Cunningham D. Managing patients treated with bevacizumab combination therapy. *Oncology* 2005;69:25-33.
 - Lordick F, Geinitz H, Theisen J, Sendler A, Sarbia M. Increased risk of ischemic bowel complications during treatment with bevacizumab after pelvic irradiation: report of three cases. *Int J Radiat Oncol Biol Phys* 2006;64:1295-8.
 - Saif MW, Elfiky A, Salem RR. Gastrointestinal perforation due to bevacizumab in colorectal cancer. *Ann Surg Oncol* 2007;14:1860-9.
 - Han ES, Monk BJ. What is the risk of bowel perforation associated with bevacizumab therapy in ovarian cancer? *Gynecol Oncol* 2007;105:3-6.
 - Gray J, Murren J, Sharma A, Kelley S, Detterbeck F, Bepler G. Perforated viscus in a patient with non-small cell lung cancer receiving bevacizumab. *J Thoracic Oncol* 2007;2:571-3.
 - Abbrederis K, Kremer M, Schuhmacher C. Ischemic anastomotic bowel perforation during treatment with bevacizumab 10 months after surgery. *Chirurg* 2008;79:351-5.
 - Heinzerling JH, Huerta S. Bowel perforation from bevacizumab for the treatment of metastatic colon cancer: incidence, etiology, and management. *Curr Surg* 2006;63:334-7.

病例報告

在轉移性大腸直腸癌病人使用 Bevacizumab (Avastin 癌思停) 後發生腸穿孔：三位病例報告

張世昌¹ 李興中¹ 沈明宏¹ 宋詠娟²

¹國泰綜合醫院 外科部 大腸直腸外科 ²內科部 血液腫瘤科

Bevacizumab (Avastin 癌思停) 是一種基因重組人類化的單株抗體，它結合到血管內皮細胞生長因子 (vascular endothelial growth factor, VEGF) 而抑制血管內皮細胞生長因子的活性，在合併化療使用下，可以延長轉移性大腸直腸癌病人的存活。腸穿孔則是在化療合併使用 *bevacizumab* (Avastin 癌思停) 治療後的一項嚴重副作用。在此我們報告三位轉移性大腸直腸癌病人在化療合併使用 *bevacizumab* (Avastin 癌思停) 治療後發生腸穿孔的情形。

關鍵詞 *Bevacizumab* (Avastin 癌思停)、腸穿孔、轉移性大腸直腸癌。