

Case Report

Metastatic Colon Cancer to the Urinary Bladder: A Case Report

Chia-Lo Chang^{1,2}

Yen-Ta Chen^{1,3}

¹*Chang Gung University College of Medicine*

²*Department of Colorectal Surgery*

³*Department of Urology, Chang Gung Memorial Hospital, Kaohsiung Medical Center, Taiwan*

Key Words

Colorectal neoplasm;

Distant metastasis;

Bladder adenocarcinoma

It is known that carcinomas arising in the organs neighboring the urinary bladder can exhibit secondary bladder involvement via direct invasion. This condition is often noted to accompany primary carcinomas of the prostate, colon or rectum, and female genital organs. However, metastasis to the urinary bladder in cases where the primary growth lies in a remote organ is considerably less common. We report the case of a 78-year-old patient in whom a primary carcinoma in the descending colon gave rise to a secondary metastatic tumor in the urinary bladder. The results of histopathological and immunohistochemical analyses confirmed the diagnosis. Although this condition is infrequently encountered in clinical practice, the possibility of metastatic involvement of the bladder should be always be considered when another primary carcinoma has been diagnosed. [*J Soc Colon Rectal Surgeon (Taiwan) 2009;20:39-43*]

Colon carcinoma is a malignant disease with a high prevalence. Clinicians are therefore considerably familiar with its sites of metastasis, which commonly involve the liver, lungs, bones, brain, and peritoneum.¹

Adenocarcinoma is an unusual form of urinary bladder carcinoma, accounting for 0.5-2% of all primary bladder malignancies.² A more common condition is adenocarcinoma originating in an organ adjacent to the bladder, typically the colon, prostate, or female genital organs, with direct metastatic invasion into the bladder. The descending colon is a rare site of origin for distant metastasis into the bladder. Here, we present and discuss a case of this rare condition.

Case Report

A 78-year-old male visited the emergency depart-

ment with the complaint of progressive abdominal distension and no stool passage for 10 days. The associated clinical manifestations included intermittent abdominal cramping, nausea, and body weight loss of 5 kg over 2 months. He had a history of head injury 12 years ago, but no other significant medical diseases. A physical examination revealed abdominal distension with mild tenderness over the left lower quadrant and without bowel sounds. No mass was palpable. Digital rectal examination revealed no rectal shelf or abnormal mass. No palpable inguinal or supraclavicular lymphadenopathy was detected.

Barium enema revealed an obstructive tumor in the descending colon with dilation of proximal bowels (Fig. 1). In addition to the lesion in the descending colon, a computed tomography (CT) scan of the abdomen and pelvis revealed an infrarenal abdominal aortic aneurysm and a 3 × 2 mass protruding into the urinary bladder and extending into the perivesicular

Received: October 8, 2008.

Accepted: March 23, 2009.

Correspondence to: Dr. Chia-Lo Chang, Department of Colorectal Surgery Department of Urology, Chang Gung Memorial Hospital, Kaohsiung Medical Center, Chang Gung University College of Medicine 123, Ta Pei Road, Niao Sung Hsiang, Kaohsiung Hsien, Taiwan. Tel: +886-7-7317123 ext. 8094; Fax: +886-7-7354394; E-mail: procto.leo@msa.hinet.net

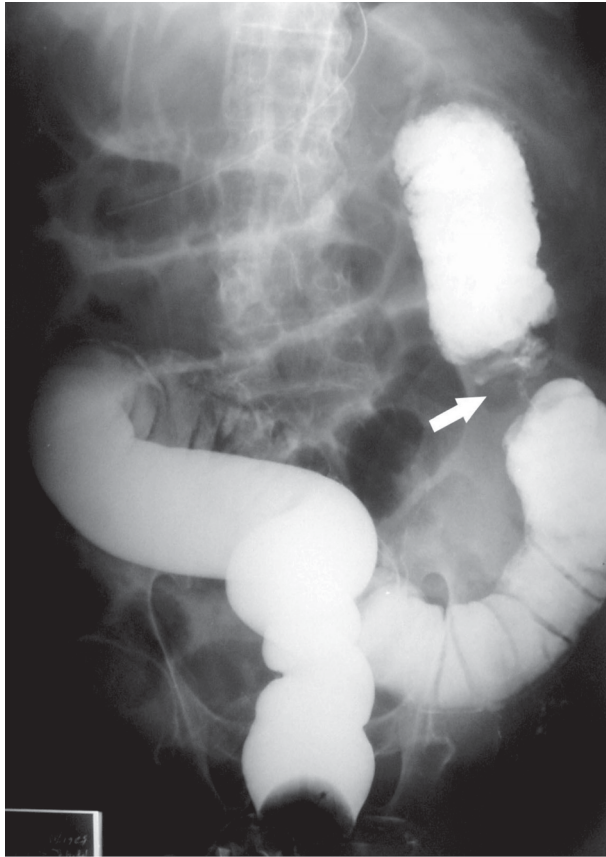


Fig. 1. Barium enema examination: Annular carcinoma (arrow) in the descending colon, with obstruction

area (Fig. 2).

A two staged surgical approach was planned as the initial step, a transverse-loop colostomy at right upper quadrant was created for stool diversion. He was readmitted 18 days later. A cystoscopic examination revealed a walnut-sized tumor in the left lateral bladder wall near the left ureteral orifice. A cystoscopic biopsy revealed a metastatic adenocarcinoma (Fig. 3) that was most probably originated in the colon. The results of immunohistochemical staining were negative for the prostate-specific antigen (PSA) but positive for the carcinoembryonic antigen (CEA) and cytokeratin 20.

Considering the diagnosis to be a descending colon carcinoma with bladder metastasis, we performed a palliative secondary stage operation involving en bloc resection of the colonic tumor and closure of colostomy and biopsy of the perivesicular tissue. There was a definite gap between the colon mass and blad-

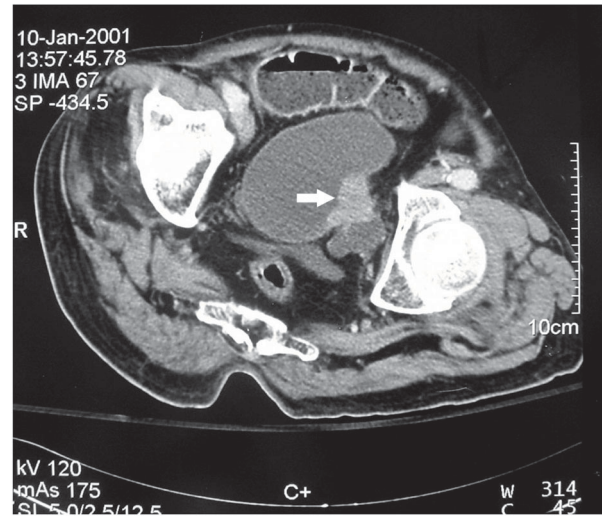


Fig. 2. CT scan of the pelvis: Bladder mass (arrow) with extension into the perivesicular area

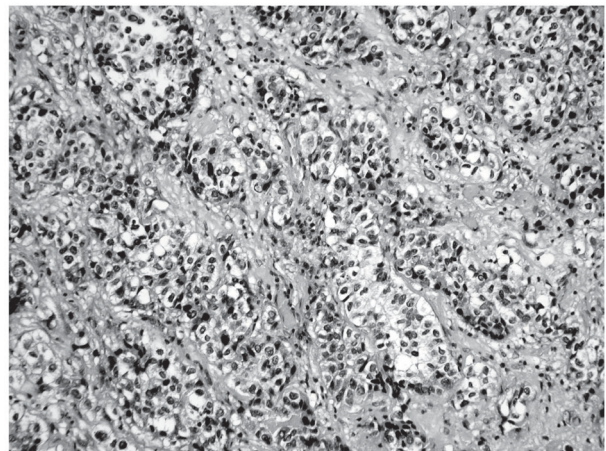


Fig. 3. Histopathological examination: Metastatic adenocarcinoma of the urinary bladder (H&E staining, 200 \times)

der tumor. The peritoneal surface showed no sign of carcinomatosis. The bladder tumor was about 0.5 cm below peritoneal surface without peritoneal involvement. Since the patient was advanced in age and no clinical symptoms of abdominal aortic aneurysm and bladder tumor, he and his family declined management of the aortic aneurysm or bladder tumor simultaneously. Pathology of the colonic tumor (Fig. 4) was a T3N1 moderate-differentiated adenocarcinoma and showed same histologic features with previous biopsy of the urinary bladder tumor.

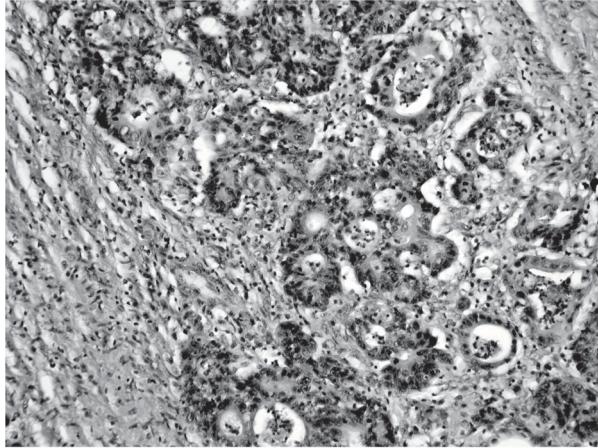


Fig. 4. Histopathological examination: Adenocarcinoma of the descending colon (H&E stain, 200 \times)

Chemotherapy consisting of 5-fluorouracil, leucovorin, and irinotecan every two weeks was given 5 weeks after surgery. Two episodes of gross hematuria occurred during the fifth course of chemotherapy, but the bleeding stopped spontaneously. Then, he refused further chemotherapy and lost follow up after 6 courses of chemotherapy. Trace back to his medical record, the patient was alive, without any symptoms of the disease at 7 months after the palliative procedure. However, he subsequently developed swelling with edema in the left leg, and pelvic CT revealed progression of the metastatic tumor and obstructive lymphadenopathy in the iliac area. The patient died 11 months after colectomy; at the time of his death, clinical evidence revealed tumor recurrence, upper gastrointestinal bleeding, and sepsis.

Discussion

Adenocarcinoma is an unusual form of bladder carcinoma, accounting for 0.5-2% of all primary bladder malignancies.² The diagnosis of urinary bladder adenocarcinoma raises the question of whether the lesion is primary; urachal; or metastatic, arising from a distant or adjacent organ.^{2,3} Distant bladder metastasis is extremely rare, and we noted the presence of a definite gap between the primary tumor and the metastatic lesion in our case.

Klinger reviewed the reports of 5,000 autopsies

that were performed at Henry Ford Hospital as part of a study on secondary tumors of the genitourinary tract: only 0.66% of the 5,000 cases (33/5000) exhibited metastatic deposits of the adenocarcinoma in the bladder.⁴ The incidence of bladder involvement in cases of colonic and rectal carcinomas was only 0.06% (3/5000). In a similar series study, Ganem and Batal et al. performed a literature review and reported 80 cases of metastatic carcinoma of the bladder. The most frequent sites of origin were the stomach (25 cases), the skin melanoma (18 cases), the female breast (16 cases), and the lungs (3 cases). The metastasis originated from the large bowel in only 4 cases (from the cecum in 1 case and the rectosigmoid in 3 cases).⁵

The precise mechanism responsible for distant bladder metastasis has not been elucidated thus far. To produce metastases, malignant cells must exhibit successful invasion, embolization, survival in circulation, arrest in a distant capillary bed, and extravasation into and multiplication in organ parenchyma.⁶ Hematuria is the most common symptom of primary bladder carcinomas because of the mucosal origin of these tumors. Our patient experienced 2 episodes of gross hematuria during chemotherapy, but the bleeding stopped spontaneously. The presence or absence of hematuria and symptoms of bladder irritability seem to depend on the ability of the tumor emboli in the bladder wall to grow rapidly, penetrate the bladder epithelium, and protrude into the bladder lumen before death occurs due to the patient's primary malignancy.³ Gross hematuria is a relatively uncommon finding in patients with metastatic tumors because ulceration of the bladder mucosa is not likely to occur. Hermann reported his pathological findings as follows: the mucous membrane is usually spared in metastatic bladder tumors originating in the gastrointestinal tract.⁷ This report was consistent with that of Sheehan and Greenberg:⁸ of 21 patients with metastatic bladder lesions, gross hematuria was noted in only 3 patients.

The detection of occult metastatic lesions demands the development of sensitive methods and markers. Immunohistochemical analysis has been shown to improve the sensitivity of histological diagnosis.⁹ In contrast to other cytoskeletal elements, the

expression of cytokeratin 20 appears to be limited to the gastrointestinal epithelial cells.¹⁰⁻¹² Its expression can be detected by immunohistochemical analysis in 95% cases of colorectal cancer.¹³ Our initial diagnosis was based on the pathological examination. Further immunohistochemical analyses confirmed these findings.

In summary, the colon is a rare site of origin for distant bladder metastasis. Although this condition is infrequently encountered in clinical practice, the possibility of metastatic involvement of the bladder should be always be considered when another primary cancer has been diagnosed.

References

1. Morson BC, Dawson IMP. *Gastrointestinal Pathology*. 4th ed, Malden Oxford: Blackwell Science 2003;1532.
2. Thomas DG, Ward AM, Williams JL. A study of 52 cases of adenocarcinoma of the bladder. *Br J Urol* 1971;43:4-15
3. Daroca PJ, Mackenzie F, Reed RJ, Keane JM. Primary adenovillous carcinoma of the bladder. *J Urol* 1976;115:41-5.
4. Klinger ME. Secondary tumors of the genitourinary tract. *J Urol* 1951;65:144-53.
5. Ganem EJ, Batal JT. Secondary malignant tumors of the urinary bladder metastatic from primary foci in distant organs. *J Urol* 1956;75:965-72
6. Gutman M, Fidler IJ. Biology of human colon cancer metastases. *World J Surg* 1995;19:226-34.
7. Hermann HB. Metastatic tumors of the urinary bladder originating from the carcinoma of the gastrointestinal tract. *J Urol* 1929;22:257-73.
8. Sheehan EE, Greenberg SD, Scott R. JR. Metastatic neoplasms of the bladder. *J Urol* 1963;90:281-4.
9. Merrie AEH, van Rij AM, Dennelt ER, Phillips LV, Yun K, McCall JL. Prognostic significance of occult metastases in colon cancer. *Dis Colon Rectum* 2003;46:221-31.
10. Wauters CC, Smedts F, Gerrits LG, Bosman FT, Ramaekers FC. Keratins 7 and 20 as diagnostic markers of carcinomas metastatic to the ovary. *Hum Pathol* 1995;26:852-5.
11. Denis MG, Lipart C, Leborgne J, et al. Detection of disseminated tumor cells in peripheral blood of colorectal cancer patients. *Int J Cancer* 1997;74:540-4.
12. Litle VR, Warren RS, Moore DN, Pallavicini MG. Molecular cytogenetic analysis of cytokeratin 20-labeled cells in primary tumors and bone marrow aspirates from colorectal carcinoma patients. *Cancer* 1997;79:1664-70.
13. Moll R, Lowe A, Laufer J, Franke WW. Cytokeratin 20 in human carcinomas. A new histodiagnostic marker detected by monoclonal antibodies. *Am J Pathol* 1992;140:427-47.

病例報告**大腸癌併遠處膀胱轉移：病例報告**張家駱^{1,2} 陳彥達^{1,3}¹長庚大學高雄長庚紀念醫院 直肛科² 泌尿科³

膀胱發生續發性腫瘤，多為骨盆腔內鄰近器官直接侵犯所引起。常造成侵犯的器官包括：前列腺癌、大腸直腸癌或子宮卵巢癌等。原發於其他器官，造成膀胱處遠處轉移的情況，則至為罕見。我們報告一例七十八歲男性，原發降結腸癌合併遠處膀胱轉移，從病理組織切片及免疫組織化學研究得到確定診斷。藉此可知，若病人已罹患癌症，又發現他處另一腫瘤時，部位雖罕見，仍必須排除原發腫瘤遠處轉移之可能。

關鍵詞 大腸直腸腫瘤、遠處轉移、膀胱腺癌。