

Original Analysis

Management of Colorectal Anastomotic Strictures Using Multidiameter Balloon Dilation

Shao-Chieh Lin¹

Edgar Sy²

Bo-Wen Lin¹

Jenq-Chang Lee¹

¹Division of Colorectal Surgery,

²Division of Pediatric Surgery,

Department of Surgery, National Cheng Kung University Hospital, Tainan City 70403, Taiwan

Key Words

Colorectal anastomotic stricture;

Balloon dilation;

Multidiameter balloon

Purpose. Postoperative benign colorectal anastomotic strictures are not rare, and a wide range of procedures has been used in their treatment, such as endoscopic dilation techniques. This study evaluates the outcome of using a specific multidiameter balloon for endoscopic dilation.

Methods. The records of 8 patients with postoperative anastomotic strictures (of less than 5 mm in diameter), with or without diverting stoma, from January 2003 to December 2006 were reviewed retrospectively. Seven patients underwent the standard endoscope-guided dilation procedure using a CRE™ wire-guided balloon dilator, resulting in closure of the diverting stoma following a successful dilation procedure.

Results. The mean duration of postoperative follow-up was 18.3 months (range, 2-41 months). Six patients had one session of balloon dilation while two had 2 sessions, with an average of 1.25 sessions/person. There was no recurrence within 18.3 months (range, 2-41 months) of follow-up (post dilation and closure of stoma). None of the patients experienced any post balloon dilation complications.

Conclusions. Endoscope-guided balloon dilation using a multidiameter balloon is a simple and safe method for managing anastomotic strictures. The diverting stoma should be closed as soon as possible following successful dilation, as stool passage acts as a natural dilator and may reduce the rate of recurrence.

[J Soc Colon Rectal Surgeon (Taiwan) 2009;20:62-68]

The appearance of benign anastomotic strictures after colorectal anastomoses is not rare,¹ occurring in 3-30% of post colorectal anastomosis, according to authors' varied definitions,^{1,2} and is considered to be related to factors including radiation,³ anastomotic ischemia or leakage,^{4,5} and suture technique.⁶⁻⁸ Most involve the middle and lower rectum^{1,2} and may spontaneously improve without treatment;⁹ however, some strictures persist, necessitating intervention using procedures such as endoscope- or fluoroscope-

guided dilation or stenting,¹⁰⁻¹⁵ re-anastomosis,^{2,16} transanal stricturoplasty and electrocautery resection, or incision, with or without dilation. The first successful trial of balloon dilation of an upper gastrointestinal tract stricture was performed in the 1980s,¹⁷ and the same procedure was subsequently used to treat strictures of the lower gastrointestinal tract.¹⁸ Balloon dilation of strictures of the gastrointestinal tract has been shown to be a convenient and effective method of treatment for most patients,¹⁰⁻¹⁵ though repeated

Received: January 8, 2009.

Accepted: April 3, 2009.

Correspondence to: Dr. Jenq-Chang Lee, Department of Surgery, National Cheng Kung University Hospital, No. 138, ShengLi Road, Tainan City 70403, Taiwan, R.O.C. Tel: +886-6-235-3535, ext. 5181; Fax: +886-6-276-6676; E-mail: leejc@mail.ncku.edu.tw

dilation may be required. Dilation can be combined with other procedures such as neodymium: yttrium–aluminum–garnet laser treatment,¹⁹ electroincision,²⁰ electrocautery,²¹ and intralesional steroid injection.²² Besides balloon dilation, endoluminal colonic wall stents,²³ self-expanding metallic stents (SEMS), and endoscopic transanal resection of strictures²⁴ may also be used. Complications associated with these procedures, including perforation and bleeding, technical failure, and stent migration, still exist.^{9,10,13-15,19,22-24} In this paper, we present our limited experience in the management of 8 cases of colorectal anastomotic stricture using endoscope-guided multidiameter balloon dilation.

Materials and Methods

Patients

Between January 2003 and December 2006, 642 consecutive colorectal patients underwent radical surgery and attended postoperative follow-up at National Cheng Kung University Hospital, Tainan, Taiwan, of which 173 had colorectal anastomosis, 42 coloanal anastomosis, and 36 ileorectal/ileoanal anastomosis. Among these patients, 8 (3.14%) were diagnosed with anastomotic stricture during the follow-up period; these cases were reviewed retrospectively in this study. Data including sex, age, etiology, types of colorectal surgery and associated colorectal procedure, surgical anastomosis technique, intraoperative condition of the anastomotic site, and postoperative complications were collected, as were data relating to the balloon dilation procedure, including duration, number of sessions, procedure-related complications, necessity of sedation, and follow-up period. All of the 8 patients underwent postoperative endoscopic examination routinely, and biopsy of the stricture site was performed in each case to exclude the presence of local recurrence.

The indication for balloon dilation in our study was a narrowed anastomosis of 5 mm or less, measured endoscopically. The distance of the stricture from the anal verge was measured during colonoscopic examination. Patients with evidence of local

recurrence were excluded. All patients underwent endoscope-guided balloon dilation using a CRE™ wire-guided multidiameter balloon dilator (Microvasive, Boston Scientific Corp., Natick, MA). Success was defined as the anastomotic lumen being wide enough to allow passage of a standard 13-mm-diameter colonoscope after dilation and the disappearance of symptoms.

Technique for balloon dilation

The balloon dilation procedure was explained thoroughly to all patients and informed consent was obtained. All patients underwent routine bowel preparation prior to colonoscope-guided balloon dilation, and the procedure was performed on an outpatient basis. The patient was positioned in the left lateral decubitus position, and propofol sedation was administered as necessary depending on patient tolerance. The stricture site was identified using a standard 13-mm-diameter colonoscope. The tip of a 7.5 F multidiameter balloon catheter with a balloon length of 5.5 cm and an inflated outer diameter of 8-10, 10-12 or 12-15 mm, a CRE™ (controlled radial expansion) wire-guided balloon dilator (Microvasive, Boston Scientific Corp., Natick, MA), was inserted through the working channel of the colonoscope and passed 2-3 cm beyond the stricture. The balloon was filled with distilled water to maintain the outer diameter at 8/10/12 mm in size and was kept in the same position for a period of 5 minutes using the standard inflation pressure (3 atm) suggested by the manufacturer; it was then deflated and withdrawn to just below the stricture site. The catheter was reapplied in the same site and the balloon re-inflated with water to keep the outer diameter to 9/11/13.5 mm (at 5.5/5/4.5 atm) for another 5 minutes, after which the stricture site was again inspected. If the stricture site was still too narrow to allow the passage of the colonoscope, balloon dilation at an outer maximal diameter of 10/12/15 mm (9/8/8 atm) was performed for a third time, either in the same session or during another session several weeks later (before closure of the colostomy) using balloons of the same or different sizes based on the operator's experience (Fig. 1).

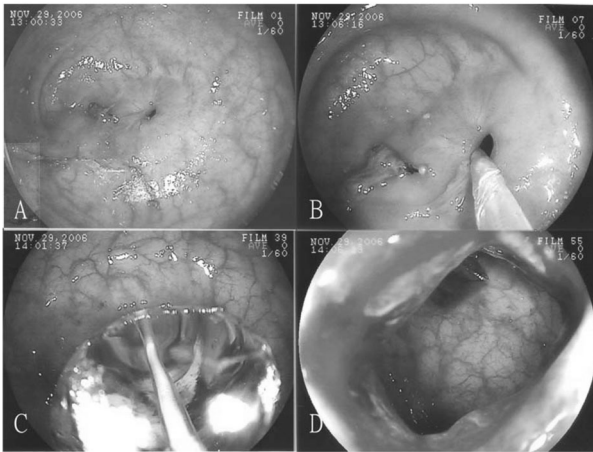


Fig. 1. A: An anastomotic stricture after colectomy under the colonoscopy. B: Placement of the guidewired balloon dilator through the stricture site. C: Expansion of the balloon. D: The appearance of the anastomosis after dilation.

Results

During the study period, a total of 8 patients were diagnosed with anastomotic stricture, 2 female and 6 male, with a mean age of 60.5 ± 9.21 years. All had colorectal adenocarcinoma and one patient had fa-

miliar adenomatous polyposis. Anastomosis was performed using the hand-sewn technique and the stapler technique in three and five cases, respectively. All patients except one had a proximal diverting stoma, which was due to insecure anastomosis in three cases (cases 2, 3 and 8) and very low rectal anastomosis (less than 5 cm from the anal verge) in four cases. No patient exhibited postoperative anastomotic leakage.

All patients were diagnosed as having anastomotic stricture by colonoscopic examination. The mean interval between the first dilation and the initial operation was 8.63 ± 4.50 months. The mean diameter of the strictures was 2.4 mm (range, 2-4 mm) (Table 1). Six patients underwent only one session of balloon dilation, while two had two sessions. No patients exhibited stricture recurrence. Only two patients were administered propofol sedation because of intolerable pain during the balloon dilation procedure. Early procedure-related complications were not noted in any of the patients. The immediate outcomes of balloon dilation and the number of sessions are summarized in Table 2. The mean follow-up period following balloon dilation was 18.3 months (range, 2-41 months); no recurrence of anastomotic stricture and symptoms was noted during follow-up.

Table 1. Patient Characteristics and Clinical Demographics

Patient No.	Age(y)/Sex	Initial Diagnosis	Initial Operation	Type of Anastomosis (size in mm)	Diverting Stoma	Radiation/Recurrence	Anastomtic Distance AAV (cm)	Interval from Initial Operation to First Dilation (mo)
1	65/F	Rectal Carcinoma	LAR	EEA [®] (28)	No	No/No	8	17
2	62/M	Rectal Carcinoma	LAR	EEA [®] (28)	Yes	No/No	7	7.5
3	64/M	Rectosigmoid Colon Carcinoma	AR	Hand-sewn Anastomosis	Yes	No/No	15	3
4	38/M	FAP ^a & Sigmoid Colon Carcinoma	Ileo-anal Anastomosis ^b	Hand-sewn Anastomosis	Yes	No/No	0	8
5 ^c	65/F	Rectal & Ascending Colon Carcinoma	Right hemicolectomy + LAR	EEA [®] (28)	Yes	No/No	5	5
6	65/M	Rectal Carcinoma	LAR	EEA [®] (28)	Yes	No/No	5	10.5 ^d
7	64/M	Rectal Carcinoma	Coloanal Anastomosis ^c	Hand-sewn Anastomosis	Yes	Yes ^f /No	0	6.5
8	61/M	Rectosigmoid Carcinoma	AR	EEA [®] (28)	Yes	Yes/No	15	11.5 ^d

^a FAP = Familial adenomatous polyposis; ^b Total proctocolectomy + J-pouch ileoanal anastomosis; ^c Case 5 received emergency right hemicolectomy, LAR, and ileostomy surgery for colorectal double cancers with total obstruction; ^d Cases 6 and 8 received adjuvant chemotherapy for longer than 6 months postoperatively; ^e Coloanal anastomosis with intersphincter resection; ^f Neoadjuvant concurrent chemoradiation therapy.

EEA[®] = stapled anastomoses; AAV = above the anal verge[®]; AR = anterior resection; LAR = low anterior resection.

Table 2. Outcome and Follow-up

Patient No.	Numbers of Dilations	Interval from Previous Dilation (wk)	Anastomotic Diameter Before Dilation (mm)	Anastomotic Diameter After Dilation (mm)	Interval from Last Dilation to Stoma Closure (day)	Follow-up Duration (mo)
1	1	-	2	14	-	2
2	1	-	4	14	60	41
3	2	46 ^a	2 and 2	10 and 14	3	2
4	1	-	2	14	92	26
5	2	4	2 and 4	10 and 14	19	16
6	1	-	2	14	119 ^b	24
7	1	-	2	14	5	3
8	1	-	2	14	33	16

^a The patient had a cardiopulmonary problem, owing to which closure of the stoma and repeated balloon dilation were delayed; ^b Case 6 received adjuvant chemotherapy for longer than 6 months postoperatively.

Discussion

Benign anastomotic stricture may occur following colorectal surgery, particularly in anterior resection of the rectum and /or cases of low rectal anastomosis.^{4,5} Multiple techniques have been used to manage colorectal anastomotic stricture, such as surgical resection and reanastomosis,^{1,2} use of a staple-cutting device,²⁵ steroid injection,²² combined use of electrocautery and laser photoablation,¹⁹⁻²¹ manual or instrumental dilation using balloon, bougie, or pneumatic dilator,⁹⁻¹⁴ or an appropriate combination of these methods.

Resection of the stricture site and re-anastomosis was traditionally performed by most surgeons in the management of anastomotic strictures, which is often associated with high morbidity and cost due to the associated presence of severe intra-abdominal or pelvic adhesion. These methods are currently used in cases of long segment stricture, especially in the presence of anastomotic leakage or post-radiation therapy, or following failure of other methods.^{1,2,16}

In our review of the literature, anastomotic strictures were found to have been treated using a variety of transanal endoscope-guided techniques, the placement of endoluminal colonic wall stents, and balloon dilation. Transanal endoscope-guided techniques include stricturotomy, using either electroincision, electrocautery, or laser ablation,^{19-21,26} and stricturoplasty, or using an auto-stapler or other special stapling device.^{25,27} The disadvantage of transanal endoscope-guided stricturoplasty using auto-staplers is the difficulty in placing the instrument in cases of a small diameter, tortuous colorectal anastomosis stricture or

one of high location far from the anal verge. Other procedures such as endoscopic transanal resection (ETAR) or transanal endoscopic microsurgery (TEMS) are used in the treatment of advanced or high typed colorectal stricture in several centers;^{28,29} however, these are technically demanding procedures and are associated with complications such as perforation and bleeding.

Placement of endoluminal colonic wall stents is carried out in benign and malignant bowel obstruction cases for immediate decompression of the bowel and as a palliative procedure for late-stage colonic malignancy patients,²³ but this procedure is complicated by stent migration, erosion and pressure ulceration of the bowel lumen, and bleeding.

The use of balloon dilation has been more widely-reported than bougie dilation and is thought to be more effective, and plays an important role in trials of endoscopic dilation of gastrointestinal strictures. Balloon dilation, either trans-endoscope-guided or fluoroscope-guided, has a success rate of more than 75%.^{9-11,15} Although balloon dilation is simple, quick and adequate for short anastomotic strictures,^{9,11} it is not suitable for long-segment strictures² or cases in which active stenotic site inflammation is present, especially Crohn's disease, in which additional steroid injection is more helpful.²² It has also been reported that this method fails to result in normal bowel function if more than three sessions are required, and an alternative treatment modality in those cases is probably needed.¹⁰

Endoscopic dilation using over-the-wire (OTW) balloons and through-the-scope (TTS) balloons has

been shown to be effective in the treatment of GI tract strictures.^{9-11,13-15,17,18,22,24,26,30} TTS dilators must be inserted through the endoscope accessory channel, while OTW-type balloons are inserted under either endoscopic or fluoroscopic control (the Seldinger method) to ensure correct positioning of the guide wire. Both dilating balloons are expanded by pressure injection of liquid or air (for achalasia), and the pressure of the balloon (radial expansion force) can be monitored using a manometrical device. Generally speaking, TTS-type balloons are smaller in diameter than OTW balloons and may produce a lesser circumferential and radial expansion force, which can affect the number of dilation sessions required and the recurrence rate. Giorgio et al.¹¹ reported that treatment of colorectal anastomotic strictures by dilation using OTW balloons involves fewer dilation sessions (1.6 vs. 2.6, $p = 0.009$) and a longer response duration (560.8 days vs. 294.2 days, $p = 0.016$); however, in patients with strictures of much smaller diameter, or in which the lesion site is far from the anal verge, it is very difficult to perform OTW-type balloon dilation under endoscopic guidance. In addition, it must be considered that radioactive rays are harmful to humans.

Balloon dilation can be performed using different types of balloons, such as single-diameter, multidiameter, hydrostatic or pneumatic balloons; the single-diameter balloon is most commonly used, and a number of patients require repeated dilation.^{9,11,13-15} Repeated dilation is suspected to be related to the stiffness of the anastomotic site, poor efficiency of the balloon, presence of local inflammation, secondary radiation therapy, active infection, leakage, or some specific conditions such as Crohn's disease. The multidiameter balloon dilator appears to have several advantages in correcting anastomotic strictures: first, the balloon is designed to deliver three distinct pressure-controlled diameters with a strong radial vector force; second, it can deliver a consistently reproducible and progressively greater dilating force with increasing diameter;³¹ and third, under endoscopic guidance the deflected tip can be placed through tight strictures and torturous anatomy without injury or difficulty. These advantages ensure a greater effectiveness of the procedure.

In our hospital, we saw our first anastomotic stricture patient in 2003 (case 4); we initially tried to use a Foley® catheter²⁶ and bougies, but this approach failed. After successful dilation using balloon dilation for this patient, we changed our protocol to indicate the routine use of TTS balloons in the treatment of anastomotic strictures. Patients with a low anterior resection or coloanal anastomosis are taught to perform digital dilation every day for one to two months after the operation in order to prevent stricture occurrence,³² with a resultant decrease in the incidence of anastomotic stricture.

In our study, the 8 patients had 10 sessions of balloon dilation in total (1.25 sessions per person). The anastomotic strictures were dilated to almost 14 mm in diameter safely on an outpatient basis without any procedure-related complications. Seven out of the eight patients had a proximal diverting colostomy, which is thought to be one of the risk factors for anastomotic stricture.³³ Closure of the stoma should be performed as soon as possible following successful dilation in the absence of any contraindication. With restoration of bowel continuity, stool passage dilates the anastomosis regularly in a natural way,³⁴ which may explain the low recurrence rate seen in our patient series.

In conclusion, in cases of severe anastomotic stricture in the presence of a diverting stoma, endoscope-guided balloon dilation using a multidiameter balloon is a simple and safe method. The diverting stoma should then be closed as soon as possible following successful dilation, as stool passage acts as a natural dilator and may reduce the rate of recurrence.

References

1. Luchtefeld MA, Milsom JW, Senagore A, Surrell JA, Mazier WP. Colorectal anastomotic stenosis. Results of a survey of the ASCRS membership. *Dis Colon Rectum* 1989;32:733-6.
2. Schlegel RD, Dehni N, Parc R, Caplin S, Turet E. Results of reoperations in colorectal anastomotic strictures. *Dis Colon Rectum* 2001;44:1464-8.
3. Anselme PF, Lavery IC, Fazio VW, Jagelman DG, Weakley FL. Radiation injury of the rectum: evaluation of surgical treatment. *Ann Surg* 1981;194:716-24.
4. Lim M, Akhtar S, Sasapu K, Harris K, Burke D, Sagar P,

- Finan P. Clinical and subclinical leaks after low colorectal anastomosis: a clinical and radiologic study. *Dis Colon Rectum* 2006;49:1611-9.
5. Hallbook O, Sjordahl R. Anastomotic leakage and functional outcome after anterior resection of the rectum. *Br J Surg* 1996;83:60-2.
 6. Baran JJ, Goldstein SD, Resnik AM. The double-staple technique in colorectal anastomoses: a critical review. *Am Surg* 1992;58:270-2.
 7. MacRae HM, McLeod RS. Handsewn vs. stapled anastomoses in colon and rectal surgery: a meta-analysis. *Dis Colon Rectum* 1998;41:180-9.
 8. Brennan SS, Pickford IR, Evans M, Pollock AV. Staples or sutures for colonic anastomoses—a controlled clinical trial. *Br J Surg* 1982;69:722-4.
 9. Johansson C. Endoscopic dilation of rectal strictures: a prospective study of 18 cases. *Dis Colon Rectum* 1996;39:423-8.
 10. de Lange EE, Shaffer HA, Jr. Rectal strictures: treatment with fluoroscopically guided balloon dilation. *Radiology* 1991;178:475-9.
 11. Di Giorgio P, De Luca L, Rivellini G, Sorrentino E, D'amore E, De Luca B. Endoscopic dilation of benign colorectal anastomotic stricture after low anterior resection: A prospective comparison study of two balloon types. *Gastrointest Endosc* 2004;60:347-50.
 12. Werre A, Mulder C, van Heteren C, Bilgen ES. Dilation of benign strictures following low anterior resection using Savary-Gilliard bougies. *Endoscopy* 2000;32:385-8.
 13. Virgilio C, Cosentino S, Favara C, Russo V, Russo A. Endoscopic treatment of postoperative colonic strictures using an achalasia dilator: short-term and long-term results. *Endoscopy* 1995;27:219-22.
 14. Skreden K, Wiig JN, Myrvold HE. Balloon dilation of rectal strictures. *Acta Chir Scand* 1987;153:615-7.
 15. Pietropaolo V, Masoni L, Ferrara M, Montori A. Endoscopic dilation of colonic postoperative strictures. *Surg Endosc* 1990;4:26-30.
 16. Swenson O, Idriss FS. Excision of rectal stricture with end-to-end anastomosis. *Arch Surg* 1966;93:54-8.
 17. London RL, Trotman BW, DiMarino AJ, Jr., Oleaga JA, Freiman DB, Ring EJ, Rosato EF. Dilatation of severe esophageal strictures by an inflatable balloon catheter. *Gastroenterology* 1981;80:173-5.
 18. Brower RA, Freeman LD. Balloon catheter dilation of a rectal stricture. *Gastrointest Endosc* 1984;30:95-7.
 19. Luck A, Chapuis P, Sinclair G, Hood J. Endoscopic laser stricturotomy and balloon dilatation for benign colorectal strictures. *ANZ J Surg* 2001;71:594-7.
 20. Truong S, Willis S, Schumpelick V. Endoscopic therapy of benign anastomotic strictures of the colorectum by electroincision and balloon dilatation. *Endoscopy* 1997;29:845-9.
 21. Brandimarte G, Tursi A, Gasbarrini G. Endoscopic treatment of benign anastomotic colorectal stenosis with electrocautery. *Endoscopy* 2000;32:461-3.
 22. Singh VV, Draganov P, Valentine J. Efficacy and safety of endoscopic balloon dilation of symptomatic upper and lower gastrointestinal Crohn's disease strictures. *J Clin Gastroenterol* 2005;39:284-90.
 23. Tamim WZ, Ghellai A, Counihan TC, Swanson RS, Colby JM, Sweeney WB. Experience with endoluminal colonic wall stents for the management of large bowel obstruction for benign and malignant disease. *Arch Surg* 2000;135:434-8.
 24. Forshaw MJ, Maphosa G, Sankararajah D, Parker MC, Stewart M. Endoscopic alternatives in managing anastomotic strictures of the colon and rectum. *Tech Coloproctol* 2006;10:21-7.
 25. Shimada S, Matsuda M, Uno K, Matsuzaki H, Murakami S, Ogawa M. A new device for the treatment of coloproctostomic stricture after double stapling anastomoses. *Ann Surg* 1996;224:603-8.
 26. Changchien CR, Tang R, Wang JY. Foley catheter-assisted endoscopic treatment of severe anastomotic stenosis following anterior resection of the rectum. *Dis Colon Rectum* 1998;41:512-3.
 27. Chew SS, King DW. Use of endoscopic titanium stapler in rectal anastomotic stricture. *Dis Colon Rectum* 2002;45:283-5.
 28. Hunt TM, Kelly MJ. Endoscopic transanal resection (ETAR) of colorectal strictures in stapled anastomoses. *Ann R Coll Surg Engl* 1994;76:121-2.
 29. Sutton CD, Marshall LJ, White SA, Flint N, Berry DP, Kelly MJ. Ten-year outcomes such as perforation, experience of endoscopic transanal resection. *Ann Surg* 2002;235:355-62.
 30. Araujo SEA, Costa AF. Efficacy and safety of endoscopic balloon dilation of benign anastomotic strictures after oncologic anterior rectal resection. *Surg Laparosc Endosc Percutan Tech* 2008;18:565-8.
 31. Goldstein JA, Barkin JS. Comparison of the diameter consistency and dilating force of the controlled radial expansion balloon catheter to the conventional balloon dilators. *Am J Gastroenterol* 2000;95:3423-7.
 32. Hayato K, Kiyonori F, Hideyuki S, Hiroyuki T, Satoshi M, Yukihiro A, Nobuhisa T, Junpei S, Takashi T. An improvement in the quality of life after performing endoscopic balloon dilation for postoperative anastomotic stricture of the rectum. *J Nippon Med Sch* 2007;74:418-23.
 33. Graffner H, F. P., Olsson SA, Oscarson J, Petersson BG. Protective colostomy in low anterior resection of the rectum using the EEA stapling instrument. A randomized study. *Dis Colon Rectum* 1983;26:87-90.
 34. Liberman H, Thorson AG. How I do it. Anal stenosis. *Am J Surg* 2000;179:325-9.
 35. Garcea G, Sutton CD, Lloyd TD, Jameson J, Scott A, Kelly MJ. Management of benign rectal strictures: a review of present therapeutic procedures. *Dis Colon Rectum* 2003;46:1451-60.

病例分析

以經大腸鏡下氣球擴張術治療大腸直腸術後 吻合處狹窄病患之成效

林劭潔¹ 施俊偉² 林博文¹ 李政昌¹

國立成功大學附設醫院 大腸直腸外科¹ 小兒外科²

目的 大腸直腸手術後所造成的吻合處狹窄時有所聞。有許多的方式被應用在處理此問題上，其中包括了重新施行吻合手術與擴張術等方式。本篇文章分析了於大腸鏡下以氣球擴張術治療本院直腸吻合處狹窄病患的成效與風險。

方法 我們於 2003 年 1 月至 2006 年 12 月間，在成大醫院共收集了 8 位直腸吻合處狹窄的大腸直腸癌病患。這些患者在大腸鏡下，接受以一具備可由小變大的氣球 (CRE™ wire-guided balloon dilator)，擴張治療狹窄處。若合併造口者，則於治療成功後數日內，將其關閉。

結果 結果顯示在平均 18.3 個月 (2 至 41 個月) 的追蹤期內，只有兩位病患須接受兩次的氣球擴張術，其餘僅需施行單次即可。此外，沒有病患有復發 (狹窄) 的情形。更重要的是，並無任何與此處置相關的併發症發生。

結論 以經內視鏡氣球擴張術來治療術後直腸吻合處狹窄的病患是一相當安全、簡便的方式。而擴張後亦須盡快將病人造口關閉，以降低或是避免因為缺乏具擴張功能的糞便經過此處所造成的再度復發。

關鍵詞 大腸直腸術後吻合處狹窄、氣球擴張術、複合式多重管徑氣球。