

Case Report

The Left Uterine Artery as an Unusual Source of Lower Gastrointestinal Hemorrhage: A Case Report

Chia-Lo Chang¹
Hong-Hwa Chen¹
Shung-Eing Lin¹
Ho Lin²

¹*Department of Colorectal Surgery;*

²*Department of Obstetrics and gynecology;
Chang Gung Memorial Hospital,
Kaohsiung Medical Center, Chang Gung
University College of Medicine, Kaohsiung
Hsien, Taiwan*

Lower gastrointestinal (GI) hemorrhage is a frequently encountered and challenging clinical problem. We report a rare case of a 30-year-old woman who presented with coexistent complications of rectal perforation and uterine arterial bleeding after pelvic surgery, exhibited recurrent massive lower GI bleeding, and developed shock. Four episodes of massive bleeding occurred before a definite diagnosis could be established by angiography. A high index of suspicion is the most important diagnostic aid that can prevent the physicians from overlooking the possibility that lower GI hemorrhage may have such an unusual source.

[*J Soc Colon Rectal Surgeon (Taiwan) 2009;20:74-78*]

Key Words

Hemorrhage;
Lower gastrointestinal bleeding;
Angiography

Lower gastrointestinal (GI) bleeding is a frequently encountered and challenging problem for clinicians. The causes of lower GI bleeding can be numerous. Diverticulosis is one of the most common causes of massive lower GI bleeding in adults. Differential diagnosis includes a wide variety of inflammatory or neoplastic conditions, anorectal disease, arteriovenous malformation, radiation proctitis, ischemic bowel disease, and even small bowel lesions.

In this report, we describe the case of a patient with recurrent massive lower GI hemorrhage. It was discovered that an upper rectal perforation and bleeding of the left uterine artery coexisted after a pelvic surgery. The possibility that the source of bleeding may be nonmesenteric in origin should be considered in patients with a history of pelvic surgery, presenting

with lower GI bleeding.

Case Report

A 30-year-old woman with primary infertility visited our gynecology clinic, presenting with the complaint of heavy menstrual flow over several months. A series of analyses revealed her condition to be due to a 5-cm uterine myoma and severe pelvic endometriosis. Enucleation of the adenomyoma and debulking of endometriosis were performed surgically. The patient's recovery course was uneventful and she was discharged on the fifth day after the surgery.

Two days after discharge the patient visited the emergency department, presenting with clinical ma-

Received: December 25, 2008.

Accepted: July 24, 2009.

Correspondence to: Dr. Chia Lo Chang, Department of Colorectal Surgery, Chang Gung Memorial Hospital, Kaohsiung Medical Center, Chang Gung University College of Medicine, 123 Ta Pei Road, Niao Sung Hsiang, Kaohsiung Hsien, Taiwan. Tel: +886-7-731-7123 ext. 8094; Fax: +886-7-735-4394; E-mail: procto.leo@msa.hinet.net

nifestations of fever with a temperature of more than 39 °C along with chills. Physical examination revealed hypoactive bowel sound, mild tenderness over the lower abdomen, and the presence of pale conjunctiva. Laboratory analysis revealed a 22% hematocrit value, 7.2 g/dL hemoglobin, and a 11,300/uL white blood cell count with a shift to the left. Computerized tomography of the abdomen and pelvis revealed a mildly dilated bowel loop and slight fluid retention in the pelvic cavity. Pelvic sepsis and anemia were suspected, and the patient was admitted to a ward to receive antibiotic treatment and blood transfusion. In the following days, her clinical symptoms improved despite persistent fever with a temperature of approximately 38 °C.

Unfortunately, a week after her admission to the hospital, the patient experienced an episode of copious hematochezia accompanied by loss of consciousness. On the next day, massive lower GI bleeding recurred. Repeated emergency angiographies demonstrated no definite extravasation of the contrast medium when a series of arterial injections was administered. After these 2 episodes, the lower GI bleeding stopped spontaneously.

The possibility of upper GI hemorrhage was ruled out by performing lavage using a nasogastric tube. Colonoscopy revealed the presence of an ulcerative lesion in the upper rectum and a dark blood clot in the rectosigmoid area. Barium enema revealed a fistula between the rectum and pelvic space (Fig. 1). Ten days later, a third hematochezia occurred. Emergency angiography was performed; the findings were negative with regard to the inferior mesenteric artery, superior mesenteric artery, and right internal iliac artery. Extravasation from the left uterine artery was observed after injecting the left internal iliac artery with the contrast medium (Fig. 2). Considering the patient's condition of primary infertility and her young age, temporary occlusion of the bleeding source was planned. Gelfoam cubes were injected after selective catheterization. A 5-French angiocatheter was retained in the left uterine artery and the patient was closely monitored for re-bleeding.

Re-bleeding occurred 2 hours after the procedure. Permanent embolization with coil springs was performed after superselective catheterization. Complete

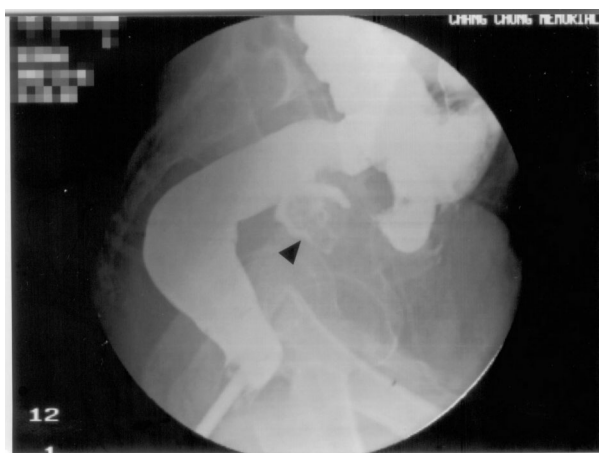

Fig. 1. Barium enema revealed a fistula tract (arrow) between the rectum and the pelvic space.

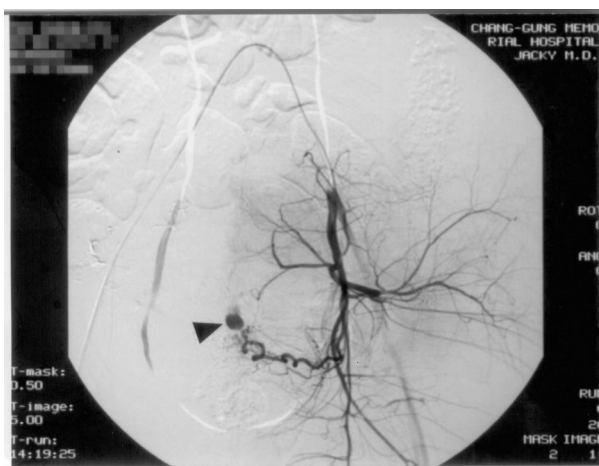


Fig. 2. Extravasation of the left uterine artery (arrow) was noted after injection of the contrast medium into the left internal iliac artery.

occlusion was confirmed by injection of the contrast medium into the internal iliac artery after embolization.

One week later, a transverse-loop colostomy was performed for diversion of fecal stream. The colopelvic fistula was left open and waited for spontaneous healing. The postoperative course was uneventful and the colostomy was closed 3 months later after barium enema proved no more fistula found.

Discussion

Lower GI bleeding is a challenging clinical prob-

lem encountered by medical and surgical gastroenterologists and it requires an efficient, detailed, and systematic evaluation. Bleeding of the entire tract distal to the ligament of Treitz can be caused by various factors, and successful management warrants accurate identification of the bleeding site before initiating a definitive therapy. Although the diagnostic methods for identifying the bleeding site have dramatically improved over the past decades, unfortunately, they have not been universally successful.¹ Technetium-99m labeled red blood cell scanning (Tc-99 RBC Scanning) is a very sensitive diagnostic tool, but it exhibits poor accuracy in identification of a bleeding site.²⁻⁶ Colonoscopy is the preferred diagnostic procedure because of its accuracy with regard to identification of the bleeding site and its therapeutic value; however, emergency colonoscopy has a limited role in cases of acute massive bleeding.^{7,8} Selective mesenteric angiography should be reserved for patients with massive bleeding for whom colonoscopy is not feasible.⁹

We report the case of a patient presenting with recurrent massive lower GI bleeding; 3 episodes of bleeding within a span of 10 days after successful enucleation of the adenomyoma and debulking of edometriosis. Casarella and Uden et al. speculated that intermittent hemorrhage may be the result of an arterial vasospasm and intermittent clotting.^{10,11} In approximately 75 to 90% of all the cases of lower GI hemorrhage, the bleeding is spontaneously arrested, allowing sufficient time for diagnostic evaluation.¹² The risk of re-bleeding varies depending on the source from which the bleeding originates. In the case of diverticular disease, the risk of re-bleeding occurring after a single episode of diverticular hemorrhage is approximately 25%, while the risk of suffering another hemorrhagic episode after 2 prior bleedings increases to 50%.¹³ Although angiodysplasias are only half as common as diverticular disease as a cause of bleeding, they are more likely to re-bleed and rarely resolved without treatment.¹⁴

Rectal perforation is a generally preventable complication associated with pelvic surgery. It may be caused by iatrogenic rectal injury, pelvic sepsis, and pressure necrosis caused by the drainage tube. Nomura et al. described 2 cases wherein bowel perforation occurred owing to the insertion of a silicone drain

placed during surgery.¹⁵ They hypothesized that the perforation was caused by pressure necrosis.

Postoperative bleeding is a possible cause of morbidity following pelvic surgical procedures, and the bleeding can usually be detected shortly after the operation. It can be clinically identified by the presence of fresh blood in the drainage tube, abdominal distention, and hypovolemic shock. We hypothesized that progressive erosion of blood vessels owing to pelvic sepsis may have caused the hemorrhage in our patient and suture absorption, a dismissed tie, and loss of embolized clot were considered to be the other possible causes.

Selective angiography has been used to evaluate lower GI hemorrhage since the 1960s.¹⁶ It can detect bleeding at a rate of 0.5-1 ml/min, and the hallmark of positive examination is extravasation of the contrast medium into the extravascular space.^{17,18} After transfemoral placement of an arterial catheter, the inferior and superior mesenteric arteries are evaluated. If the mesenteric vessels do not exhibit a bleeding site, then the celiac axis and internal iliac arteries are sequentially examined to detect the site of nonmesenteric bleeding. Postoperative bleeding can usually be found at the previous operation field and the clinical condition determines the sequence in which the vessels should be studied. Our patient had previously undergone a pelvic surgery and presented with massive low GI bleeding. Sequential angiography was performed for the inferior and superior mesenteric arteries followed by the internal iliac arteries which were reasonable and mandatory.

In summary, lower GI bleeding is a challenging clinical problem that requires a detailed and systematic approach. Coexisting complications such as rectal perforation and bleeding of the left uterine artery occur very rarely after pelvic surgery. We described a patient presenting with recurrent bleeding in the lower GI tract, and the left uterine artery was identified as the bleeding source. The possibility that the lower GI bleeding may be nonmesenteric in origin should be considered in patients with history of a pelvic surgery. A high index of suspicion is the most important diagnostic aid that can prevent physicians from overlooking the possibility that lower GI hemorrhage may have such an unusual source.

References

1. Vernava AM III, Moore BA, Longo WE, Johnson FE. Lower gastrointestinal bleeding. *Dis Colon Rectum* 1997;40:846-58.
2. Alavi A, Dann RW, Baum S, Biery DN. Scintigraphic detection of acute gastrointestinal bleeding. *Radiology* 1977;124:753-6.
3. Bentley DE, Richardson JP. The role of tagged red blood cell imaging in the localization of gastrointestinal bleeding. *Arch Surg* 1991;126:821-4.
4. Nicholson ML, Neoptolemos JP, Sharp JF, Watkin EM, Foscard DP. Localization of lower gastrointestinal bleeding using in-vivo technetium-99m-labeled red blood cell scintigraphy. *Br J Surg* 1989;76:358-61.
5. Gupta N, Longo WE, Vernava AM III. Angiodysplasia of the lower gastrointestinal tract: an entity readily diagnosed by colonoscopy and primarily managed nonoperatively. *Dis Colon Rectum* 1995;38:979-82.
6. Kester RR, Welch JP, Sziklas JP. The 99mTc-(Tc-labeled) labeled RBC scan. A diagnostic method for lower gastrointestinal bleeding. *Dis Colon Rectum* 1984;27:47-52.
7. Jensen D, Machicado G. Diagnosis and treatment of severe hematochezia. *Gastroenterology* 1988;95:1569-74.
8. Rossini FP, Ferrari A, Spandre M, Cavallero M, Gemme C, Loverci C, Bertone A, Pintor MP. Emergency colonoscopy. *World J Surg* 1989;13:190-2.
9. Fan CY, King TM, Wang JH, Chien LC, Liang CL. Evaluation and management of acute lower gastrointestinal bleeding. *J Soc Colon Rectal Surgeon (Taiwan)* 2001;12:81-8.
10. Casarella WJ, Galloway SJ, Tasin RN, et al. Lower gastrointestinal tract hemorrhage: new concepts based on arteriography. *Am J Roentgenol* 1974;121:357-68.
11. Uden P, Jiborn H, Jonsson K. Influence of selective mesenteric arteriography on the outcome of emergency surgery for massive, lower gastrointestinal hemorrhage: a 15-year experience. *Dis Colon Rectum* 1986;29:561-6.
12. Farrands PA, Taylor I. Management of acute lower gastrointestinal hemorrhage in a surgical unit over a 4-year period. *J Roentgenol Soc Med* 1987;80:79-82.
13. McGuire JJ Jr, Haynes BW Jr. Massive hemorrhage from diverticulosis of the colon: guideline for therapy based on bleeding patterns observed in fifty cases. *Ann Surg* 1972;175:847-53.
14. Boley SJ, Bibiase A, Brandt LJ, Sammartano RJ. Lower intestinal bleeding in the elderly. *Am J Surg* 1979;137:57-64.
15. Nomura T, Shirai Y, Okamoto H, Hatakeyama K. Bowel perforation caused by silicone drains: A report of two cases. *Surg Today Jpn Surg* 1998;28:940-2.
16. Nussbaum M, Baum S, Blakemore W, Blakemore WS, Finkelestein AK. Demonstration of intraabdominal bleeding by selective arteriography. *JAMA* 1965;191:389-90.
17. Baum S, Rosch J, Dotter CT, Ring EJ, Athanasoulis C, Waltman AC, Courey WR. Selective mesenteric arterial infusions in the management of massive diverticular hemorrhage. *N Engl J Med* 1973;288:1269-72.
18. Vander Vliet AH, Kalff V, Sacharias N, Kelly MJ. The role of contrast angiography in gastrointestinal bleeding with the advent of technetium labeled red blood cell scans. *Aust Radiol* 1985;29:29-42.

病例報告**左側子宮動脈引起下消化道出血：病例報告**張家駱¹ 陳鴻華¹ 林尙穎¹ 林 浩²長庚大學 高雄長庚紀念醫院 直肛科¹ 婦產科²

下消化道大量出血對臨床醫師而言，是相當具有挑戰性的問題。報告一例三十歲女性，在婦科骨盆腔手術後，同時併發直腸破裂和子宮動脈出血，臨床表現出反覆大量下消化道出血及休克的罕見病例。病人在經歷四次動脈血管攝影後出血才得到確切控制，唯有臨床高度懷疑且快速準確的動脈血管攝影檢查，才可避免輕忽此一罕見下消化道出血原因，並得到立即有效的治療。

關鍵詞 出血、下消化道出血、血管攝影術。