

**Case Report**

# **Cytomegalovirus Colitis in an Immunocompetent Patient: Report of a Case and Review of the Literature**

Mong-Wei Lin  
Jin-Tung Liang  
King-Jen Chang  
Po-Huang Lee  
Been-Ren Lin

*Department of Surgery, National Taiwan University Hospital, College of Medicine, National Taiwan University, Taipei, Taiwan.*

---

**Key Words**

Cytomegalovirus;  
Colitis;  
Immunocompetent

Most cases of cytomegalovirus (CMV) colitis occur in immunocompromised patients, including those with congenital or acquired immunodeficiency disease, those receiving immunosuppressive drugs, and transplant patients. Only a small number of immunocompetent patients with CMV colitis have been reported worldwide. We describe the first case reported in Taiwan. This 86-year-old man was initially treated for presumed ischemic colitis after a series of laboratory and image studies. Fever and abdominal pain persisted despite empirical treatment with antibiotics. Left hemicolectomy was performed one month after admission. Inclusion bodies characteristic of CMV infection were identified in surgical specimens. The patient recovered after the operation. We review the medical literature on the clinical features, diagnosis, prognosis, and treatment of CMV colitis in immunocompetent patients. Surgery is the choice of therapy for patients with colonic perforation, persistent gastrointestinal bleeding, toxic megacolon, or any other severe complication. We suggest that repeat biopsies be performed on any patient with a highly suspected case of CMV colitis, and that antiviral therapy may not be necessary after surgical treatment in selected immunocompetent patients with underlying CMV infection. [*J Soc Colon Rectal Surgeon (Taiwan) 2008;19:27-32*]

---

**C**ytomegalovirus (CMV) colitis mainly occurs in immunocompromised patients, including those with congenital or acquired immunodeficiency disease, those receiving immunosuppressive drugs, and transplant patients. Cytomegalovirus in immunocompetent patients is an uncommon clinical entity. We describe the first such case reported in Taiwan. Since immunocompetent patients with CMV colitis are very rare, we review the medical literature on their clinical features, diagnosis, prognosis, and treatment.

## **Case Report**

An 86-year-old man with a history of diabetes mellitus, hypertension, and chronic hepatitis C, but not of gastrointestinal disorders, was admitted to our hospital with nausea, vomiting, and diffuse abdominal pain for one day. The patient had had severe constipation for six years, but now complained of diarrhea over the past several days. He denied noticing bloody stools, had no other significant past medical or travel history, and did not smoke or drink alcohol.

---

Received: August 21, 2007.

Accepted: April 23, 2008.

Correspondence to: Dr. Been-Ren Lin, Department of Surgery, National Taiwan University Hospital, 7 Chung-Shan South Rd. Taipei 10002, Taiwan. Tel: +886-2-23123456 ext: 5919; Fax: +886-2-23934358; E-mail: dtsurg92@yahoo.com.tw

On physical examination, he appeared stable with a body temperature of 36.2 °C, blood pressure of 95/48 mmHg, and heart rate of 75 beats per minute. Head and neck examination revealed no abnormalities. Cardiovascular examination was unremarkable. Breathing was unlabored and breath sounds were clear. The only positive finding was diffuse abdominal tenderness with peritoneal signs.

Initial laboratory studies were significant for a leukocyte count of 15,580/ $\mu$ l with bandemia of 33%, blood urea nitrogen of 35.1 mg/dL, serum creatinine of 1.9 mg/dL, and 3+ occult blood in his stool. Hemoglobin, hematocrit, serum electrolyte, alanine aminotransferase, aspartate aminotransferase, urine analysis, and other studies were all within normal ranges.

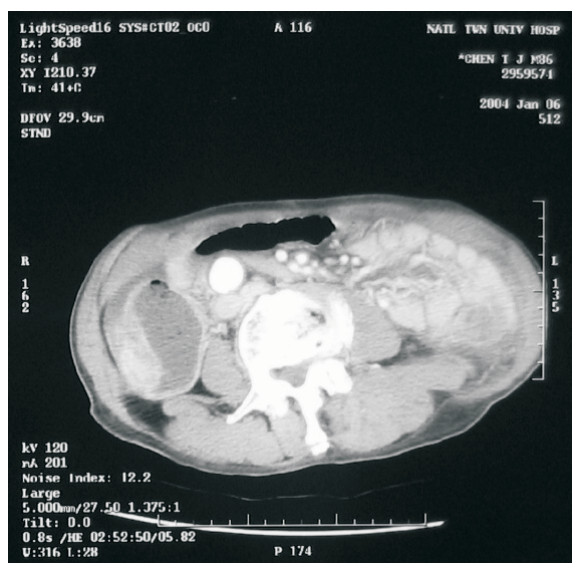
Chest and abdominal x-rays were unremarkable. Contrast-enhanced abdominal computed tomography revealed diffuse enlargement of the descending and sigmoid colon (Fig. 1). Colonoscopy was performed and revealed multiple hematoma and ulcerative changes, 35 cm above the anal verge. Biopsy revealed ulcerated colonic mucosa with no evidence of microorganisms.

Given a presumptive diagnosis of ischemic colitis, the patient received conservative treatment, including restriction of all oral intake, antibiotic therapy with cefmetazole, and intravenous fluid and nutrition, as of the first hospital day. Persistent bloody diarrhea was noted, however. On the second hospital day, his body

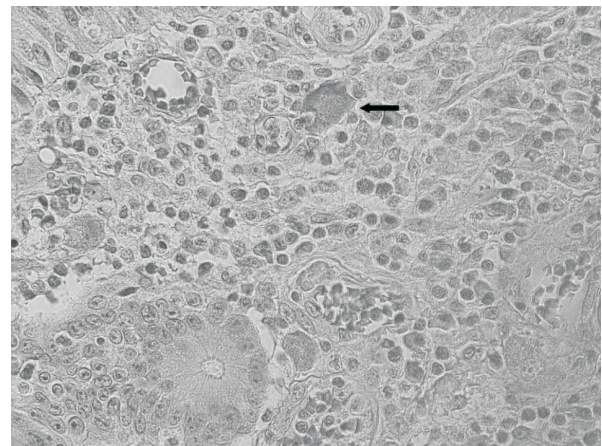
temperature started to rise and remained elevated. On the 3rd hospital day, C-reactive protein level was 8.52 mg/dL, hemoglobin 8.5 g/dL, and hematocrit 24.9%. Bacterial cultures of blood, urine and stool were negative. With conservative treatment, his condition improved gradually. He was allowed to drink a bit of water on the 8th hospital day and started a soft diet the next day, due to improved symptoms.

However, intermittent high fever, elevated C-reactive protein levels, and anemia persisted into the third and fourth hospital weeks, despite continued empirical antibiotic use and blood component therapy. Abdominal tenderness and fullness also persisted. Due to persistent fever, abdominal pain, and anemia, he ultimately underwent left hemicolectomy on the 30th hospital day, again with a presumptive diagnosis of ischemic colitis refractory to conservative management. Operative findings included the absence of any inferior mesenteric artery pulsation, and ischemic changes of the descending and sigmoid colon. The upper descending colon was swollen and distended. The lower descending and sigmoid colon revealed stenotic changes, including thickened walls.

Histopathologic examination revealed severe active colitis, with multiple deep ulcers and focal subserosal fibrosis. The surrounding mucosa demonstrated regenerative change. In addition, enlarged cells with intra-nuclear inclusion bodies, consistent with CMV-infected cells, were noted at the ulcerative sites (Fig. 2). Post-operative serum IgM anti-CMV



**Fig. 1.** Computed tomography scan revealed diffuse enlargement of the descending and sigmoid colon.



**Fig. 2.** Surgical specimens from resected colonic tissue demonstrated classic cytomegalovirus inclusion bodies (arrow).

antibody levels were elevated. HIV serology was negative.

An infectious disease specialist recommended the empirical use of an antiviral drug, even though currently there is no evidence in support of the use of post-operative antiviral medication in immunocompetent CMV colitis patients. The option of anti-viral therapy was discussed with the patient, who ultimately refused due to possible side effects. Fortunately, his fever subsided gradually post-operatively, and his symptoms of colitis improved as well. He was discharged on the 44th hospital day. He remained asymptomatic without recurrence over the next 32 months of follow-up.

## Discussion

CMV is a common human viral infection, with 40% to 100% of adults exhibiting evidence of past seroconversion. However, under most circumstances, symptoms are absent or self-limited. Serious CMV infection usually occurs in patients with immune deficiency, for example, from organ transplantation, malignancy, congenital or acquired immunodeficiency syndromes, steroid therapy, or chemotherapy. There are only a relatively few case reports of CMV colitis in immunocompetent patients.<sup>1-7</sup> Acute infections in an immunocompetent host are almost always asymptomatic. However, there is a lifelong latency accompanied by the risk of reactivation.<sup>8</sup> CMV colitis in immunosuppressed patients almost always occurs secondary to latent CMV infection reactivation. However, in the immunocompetent patient, CMV colitis is usually related to primary infection.<sup>2</sup>

In the literature, most immunocompetent patients with CMV colitis were older than 55 years old, with an average age of 61 years. The overall mortality rate was 32%.<sup>3</sup> The sigmoid colon was the most frequently involved site in immunocompetent patients, which differs from the cecum in immunocompromised patients. Our patient was similar. Clinically, immunocompetent patients with CMV colitis commonly presented with a triad of diarrhea, fever, and abdominal pain.<sup>4</sup> In a comprehensive review of the literature on CMV colitis in immunocompetent patients, diarrhea

was the most common presenting symptom being evident in 82%, with bloody and watery diarrhea present in 53% and 29%, respectively. Fever was present in 76%, and abdominal or rectal pain was reported in 53% of the patients.<sup>5</sup> Other reported symptoms include urgency, tenesmus, general malaise, anorexia, and weight loss. Although some patients recovered spontaneously, many patients suffered from severe complications, such as bowel perforation, severe gastrointestinal bleeding, and toxic megacolon. The symptoms of CMV colitis can mimic ischemic colitis, pseudomembranous colitis, and colitis associated with other pathogens. Therefore, in any patient with bloody or watery diarrhea, fever, abdominal pain, and negative stool cultures, CMV colitis should always be on the list of differential diagnoses.

Several review articles have been written about the prognostic factors of CMV colitis in immunocompetent patients. Poor prognostic factors are being male or older than 55, having some immune-modulating disease, requiring colectomy, and having no prior history of colonic injury.<sup>3,6</sup> CMV colitis in immunocompetent patients with preceding colonic injury - for example, as a result of anal intercourse, amebiasis, or Shigella dysentery - typically resolves as the initial colonic injury heals. In one review, all nine cases of CMV colitis related to colonic injury received only supportive treatment, and all were resolved without major complications.<sup>6</sup> In contrast, those patients without a previous colonic insult may have a poor prognosis. One review article revealed that only 3 of 15 patients without a previous colonic insult had a self-limited course.<sup>2</sup> Five of these patients required surgical treatment, and four patients died. One possible explanation for this latter result may be that patients without a preceding colonic injury generally require a higher viral load, leading to a more severe systemic CMV disease. Besides, some of these patients may have had underlying diseases that immunocompromised them to some degree.

There are various diagnostic tools for CMV colitis, including serologic analysis, viral cultures, antigen studies using polymerase chain reactions, imaging studies, and histological review of endoscopic or surgical biopsy specimens. The gold standard for diagnosis is identifying CMV inclusion bodies at af-

ected sites.

Because of the high prevalence of IgG anti-CMV antibodies in the normal population, this study is not helpful for diagnosing CMV colitis. The presence of IgM anti-CMV antibodies corresponds to recent CMV infection, but their presence does not establish the diagnosis of tissue-invasive disease. Furthermore, a negative result occurs in more than 10% of patients with active CMV infection. CMV virus culture is not helpful clinically, because it requires several weeks to obtain results. Moreover, CMV stool cultures are positive in only one third of patients with documented CMV colitis. Detection of CMV antigen or DNA in the blood is more sensitive and takes less time than viral cultures. Therefore, polymerase chain reaction assays on blood might serve as a useful tool for diagnosing CMV infection.<sup>8</sup>

Abdominal computed tomography (CT) and barium enema are the most useful imaging studies for CMV colitis. Classic findings include a thickened bowel wall, inflammatory infiltration, bowel lumen strictures, and mucosal irregularity and ulceration. Although these two imaging studies are highly sensitive, the findings are nonspecific for CMV colitis and can be present in colitis of any etiology.<sup>9,10</sup>

A definitive diagnosis of CMV colitis depends upon an invasive procedure with resultant tissue biopsy. Colonoscopic biopsy is the method usually used. CMV colitis usually appears as a mucosal erosion or ulceration upon endoscopic examination. The diagnosis depends upon characteristic pathological changes in the biopsy specimen. Full colonoscopic examination can identify more CMV colitis patients than flexible sigmoidoscopic examination. Some patients are diagnosed with CMV colitis by means of surgical specimens obtained during bowel resections, as with the patient presented in this article. Histologically, CMV colitis is characterized by basophilic intranuclear inclusions, each surrounded by a halo, the so-called "owl's eye". As stated earlier, this finding is regarded to be the gold standard for the diagnosis of CMV colitis.<sup>8</sup>

The treatment of CMV colitis appears to be divided into supportive, antiviral and surgical treatment. Two antiviral drugs, Ganciclovir and Foscarnet, have been suggested for use, based upon some limited evi-

dence, and have been widely used for immunocompromised patients with CMV colitis.<sup>8</sup> The indications for antiviral drug therapy in immunocompetent patients with CMV colitis remain controversial.<sup>3,5,6</sup> Patients with complications like colonic perforation, severe gastrointestinal bleeding, and toxic megacolon often require surgery. Our experience with this one patient was that antiviral drugs were unnecessary in a patient who had undergone surgical intervention and whose condition was stable post-operatively.

In summary, we described a case of CMV colitis involving an immunocompetent patient, whose initial presentation included vomiting, abdominal pain and diarrhea. He received surgical treatment one month after admission and recovered without post-operative antiviral drug therapy. Although CMV colitis is rare in immunocompetent patients, one must always consider it in the list of differential diagnoses in patients with diarrhea, fever, abdominal pain, and negative stool cultures. We suggest that repeat biopsy be performed in patients in whom there is significant suspicion of CMV colitis. Moreover, antiviral therapy may not be necessary after surgical treatment in selected immunocompetent patients. Surgery often is the intervention of choice in patients with colonic perforation, persisted gastrointestinal bleeding, toxic megacolon, and other severe complications.

## References

1. Hamlin PJ, Shah MN, Scott N, Wyatt JI, Howdle PD. Systemic cytomegalovirus infection complicating ulcerative colitis: a case report and review of the literature. *Portgrad Med J* 2004; 80:233-5.
2. Klauber E, Briski LE, Khatib R. Cytomegalovirus colitis in the immunocompetent host: an overview. *Scand J Infect Dis* 1998;30:559-64.
3. Galiatsatos P, Schrier I, Lamoureux E, Szilagyi A. Meta-analysis of outcome of cytomegalovirus colitis in immunocompetent hosts. *Dig Dis Sci* 2005;50:609-16.
4. Siegal DS, Hamid N, Cunha BA. Cytomegalovirus colitis mimicking ischemic colitis in an immunocompetent host. *Heart Lung* 2005;34:291-4.
5. Karakozis S, Gongora E, Caceres M, Brun E, Cook JW. Life-threatening cytomegalovirus colitis in the immunocompetent patient: report of a case and review of the literature. *Dis Colon Rectum* 2001;44(11):1716-20.

6. Lee CS, Low AH, Ender PT, Bodenheimer HC Jr. Cytomegalovirus colitis in an immunocompetent patient with amebiasis: case report and review of the literature. *Mt Sinai J Med* 2004;71:347-50.
7. Ng FH, Chau TN, Cheung TC, King C, Wong SY, Ng WF, Lee KC, Chan E, Lai ST, Yuen WC, Chang CM. Cytomegalovirus colitis in individuals without apparent cause of immunodeficiency. *Dig Dis Sci* 1999;44:945-52.
8. Goodgame RW. Gastrointestinal cytomegalovirus disease. *Ann Intern Med* 1993;119:924-35.
9. Teixidor HS, Honig CL, Norsoph E, Albert S, Mouradian JA, Whalen JP. Cytomegalovirus infection of the alimentary canal: radiologic findings with pathologic correlation. *Radiology* 1987;163:317-23.
10. Cho SR, Tisnado J, Liu CI, Beachley MC, Shaw CI, Kipreos BE, Schneider V. Bleeding cytomegalovirus ulcers of the colon: barium enema and angiography. *AJR AM J Roentgenol* 1981;11:241-6.

## 病例報告

# 免疫正常病患之巨細胞病毒大腸炎： 病例報告及文獻回顧

林孟暉 梁金銅 張金堅 李伯皇 林本仁

國立台灣大學附屬醫院 外科部

巨細胞病毒大腸炎好發於免疫不全病患，包括先天或後天免疫不全，服用免疫抑制劑，器官移植等病患。發生在免疫正常病患的巨細胞病毒大腸炎相當少見，只有少數病例在國外醫學文獻上被報告過，而在台灣，並沒有任何免疫正常病患發生巨細胞病毒大腸炎的病例被報告過。我們報告一位八十六歲的男性病患，一開始懷疑是缺血性大腸炎，接受抗生素及保守性治療後，發燒，腹痛症狀以及消化道出血仍然持續。病患於住院後一個月接受左側大腸切除手術，術後的病理切片呈現典型巨細胞病毒的細胞內包涵體。病患術後恢復良好，順利出院。我們在此篇論文中，回顧醫學文獻中關於免疫正常病患的巨細胞病毒大腸炎，包括臨床特徵，診斷方式，治療以及預後。我們建議當病患出現大腸穿孔，持續消化道出血，毒性巨結腸症等嚴重的併發症時，便需要進一步的手術治療。病患懷疑是巨細胞病毒大腸炎時，可能需要一次以上的切片以確定診斷。另外，根據我們的經驗，病患接受手術之後，並不需要一律給予抗病毒藥物。

**關鍵詞** 巨細胞病毒、大腸炎、免疫正常病患。